

~~FOR OFFICIAL USE ONLY~~

~~CONFIDENTIAL~~

27771

ATOMIC BOMB CASUALTY COMMISSION

Preliminary Report

Medical Report on the Fukuryu Maru No. 5 Incident

by

John J. Morton, M.D., Director, ABCC

Jack J. Lewis, Lt., MC, USNR, Head of Medicine, ABCC

Seichi Shimomura, M.D., ABCC

Takashi Fujii, M.D., ABCC

Mary Sears, M.D., ABCC

Katsumi Tsuchitori, Chief Technician, ABCC

US DOE ARCHIVES	
326 US ATOMIC ENERGY	
COMMISSION	
RG	
Collection	<i>DBM</i>
Box	<i>326-78-3, Box 3</i>
Folder	<i>Rpts. on Fukuryu Maru</i> <i>No. 5 Incident</i>

Submitted: 26 March 1954

STATUS VERIFIED *UNCL*
BY *Jac. King* DATE *3/24/81*

NON-CCRP

~~FOR OFFICIAL USE ONLY~~

Preliminary Report

TABLE OF CONTENTS

	<u>Page</u>
INTRODUCTION	1
Background and significance	
CASE HISTORIES	
Tokyo cases, T-1, T-2	5
Yaizu cases, T-3, T-5, T-16, T-18, T-19, T-22	13
CHART OF RADIATION SIGNS AND SYMPTOMS IN ALL PATIENTS	21
HEMATOLOGY REPORT	23
HEMATOLOGY RESULTS	
Tokyo patient T-1	25
T-2	26
Bone marrows, Tokyo patients	27
Yaizu patients	
White blood cell counts	28
Differentials	29
Red blood cells and hemoglobin	30
Bone marrows, Yaizu patients	31
RADIO ACTIVITY SURVEY	
Tokyo patient T-1	32
T-2	34
SHIP	36
Crude drawing of ship	37
Radio activity of ship	38
SUGGESTIONS	39
PHOTOGRAPHS OF TOKYO PATIENTS	
T-1	40
T-2	48

~~SECRET~~
~~CONFIDENTIAL~~
INTRODUCTION

Sometime in the early morning hours of 1 March 1954, an atomic weapon of unknown composition was detonated on Bikini Island. According to unofficial versions, the bomb was of immense power.

Some 80 to 110 miles east of Bikini, a Japanese fishing vessel had put out its lines. Upon seeing the flash the ship's captain immediately steered the ship towards the East away from the island. Approximately two hours later, while the crew was feverishly bringing the lines and catch aboard, the sky darkened and there was a shower of fine ash-like material lasting four and a half hours. The crew stated the "ash shower" came towards them propelled by and East wind.

When members of the ship's complement began showing evidence of eye irritation, malaise and nausea, to be followed later by skin pigmentation and vesiculation, the vessel sailed for its home port of Yaizu, Japan. On this return trip the crew members washed the decks, bulkheads, clothing, and themselves in an effort to rid themselves of some unknown factor. Upon landing in Yaizu, the ship's captain ordered his entire crew to the local hospital for checkups, before going to sea again. The signs and symptoms of these men were highly suspicious of radiation sickness, to the local physicians. The two sickest crewmen were sent to Tokyo which started a chain of events leading to the realization that the crew, vessel, and catch had been contaminated with radioactive materials. Steps were immediately taken to confiscate the cargo of fish (mainly tuna and shark), though the crew had partaken of smaller fish caught during the fall out.

The significance of this unfortunate incident cannot be over estimated because of the following facts:

~~CONFIDENTIAL~~
~~CONFIDENTIAL~~

~~CONFIDENTIAL - SECURITY INFORMATION~~
1. For the first time a population has been subjected to a highly radioactive fall out for an appreciable length of time.

2. This small population was only radiated and there could not be the other factors of blast and heat.

3. This radiated group, because of the circumstances, was forced to live in a radioactive contaminated shelter, wear radioactive clothes, eat radioactive food, and wash with radioactive water.

4. For the first time a group has respired in a radioactive atmosphere for several hours.

5. For the first time a group has eaten highly radioactive foods.

6. There is the highly relevant question of a ship fleeing towards the East from an event in the West, running into a radioactive dust coming towards it from the East.

7. How will the signs and symptoms of the fall out effects differ from the radiation effects of the Hiroshima and Nagasaki bombs?

8. Lastly, what will be the ultimate fate of these men not only in terms of days or years; but in terms of their age of death, cause of death, procreation, genetic mutations, etc.?

At the request of the Atomic Energy Commission, the director of the Atomic Bomb Casualty Commission was asked to proceed to Tokyo to determine the condition of two patients who were reported to be there. He was instructed to make as careful an appraisal as he could of their present status and of their progress since arrival on March 15th. These two patients were considered to be the most seriously injured of the crew and had been taken to Tokyo University Hospital where Japanese experts would be responsible for their examination and treatment.

~~CONFIDENTIAL~~
~~CONFIDENTIAL~~
~~CONFIDENTIAL~~
It was indicated that after this survey that it would be highly desirable to see the other members of the crew at Yaizu; to make appropriate examination of them, and to render any assistance possible to all the patients. The ship "Fukuryu Maru" was to be monitored for evidence of residual radiation activity and reports on all the above to be sent to Washington as expeditiously as possible.

Arrangements to get to Tokyo quickly were facilitated by the assignment of a C-47 by the USAF which brought us to Tokyo on Thursday, March 18th, landing at the airport at 1300. The team selected from A.B.C.C. staff to take part in this activity were:

LT. Jack J. Lewis, USNR, Acting Chief of Medicine

Dr. Seichi Shimomura, General Medicine - bilingual

Dr. Takashi Fujii, Medicine, Hematologist - bilingual

Dr. Mary Sears, Medicine, Hematologist

Miss Katsumi Tsuchitori, Laboratory Technician, very experienced hematologist

The proper Japanese authorities were contacted and arrangements made to examine the patients at Tokyo University Hospital on March 16th. Dr. Masao Tsuzuki was cooperative and helpful. A complete physical examination of these patients was obtained and is here subtended in the body of the report.

There being no radiation physicists in the A.B.C.C. group, assistance was asked of the Armed Forces. General Standlee offered the services of men in his Command who had been trained in this discipline. Colonel McNinch was put in charge of this group. The Air Force also supplied a competent team under Lt. Col. Arthur Keek.

The second phase of the investigation at Yaizu was carried out on March 20. A C-47 plane took us down and back. The medical group and the radiation physicists

~~CONFIDENTIAL~~
~~CONFIDENTIAL~~
~~CONFIDENTIAL~~
CONFIDENTIAL

~~CONFIDENTIAL~~

were joined by Dr. Nakaidzumi, Dr. Nagai and Dr. Maki for coordination of this effort. Dr. Nakaidzumi, professor of Radiology at Tokyo University, had monitored the ship and had seen the patients several times since they had landed on March 14th at Yaizu. Dr. Nagai and Dr. Maki represented the National Institute of Health (Dr. Maki acts as Co-director of the A.B.C.C. in Hiroshima). Dr. Nakaidzumi was of the greatest assistance to us. He guided us over the ship, indicated the spots which were of special interest. He allowed us to take whatever samples we desired. He conducted us to the fish market and made available the fish which had been saved for scientific purposes. He took us to the hospital and had the physicists use their Geiger counters on the hair, nails, etc., of the patients.

All 21 patients had been assembled in the hospital there. Four of the most seriously injured according to their low white counts, and three others as a sample of the remaining 15 patients were examined. This study will be added in the body of the report.

The report of the radiation studies will be supplied by Colonel Meek. Dr. Nakaidzumi has promised to give us complete information on his monitoring of the ship from the first date he examined it up to and including his last examination as of March 21. This will be added to Colonel Meek's report.

~~CONFIDENTIAL~~
~~CONFIDENTIAL~~
CASE HISTORIES

In the following accounts of what befell various crew-members of the "Fukuryu Maru", it must be strongly emphasized that of all the 23 men only the two Tokyo patients were adequately examined. Even in these latter cases, all laboratory reports are from the Tokyo University Hospital's charts, which were generously opened to the A.B.C.C. physicians. The 21 cases at Yaizu were sketchily reviewed. There were seven less than adequate case histories and physical examinations. The A.B.C.C. personnel were not allowed to perform any laboratory tests. Because of the restrictions in time and examining facilities, the four patients with a white blood cell count below 4000 at any time (most severe category) and three other patients, whose white blood cell counts were within the normal range (less severe category) were examined. Thus a total of nine cases were seen.

MASUDA, Sanjiro T-1

This patient felt well until 1 March 1954. At about 4 a.m. March 1, 1954, he saw a red flash on the horizon to the east (this was through the cabin window). He immediately went out on the deck and through dark glasses viewed the flash, which continued to be evident for three minutes. The skipper of the ship thought the flash was due to an atomic bomb and, therefore, ordered the bringing in of the fishing lines. Five minutes after the flash there was a loud blast and two minutes later there were two faint reports. About one and one-half hours later the patient noticed a darkening of the sky and then there was a shower of ash or dust. At this time the ship was running toward the east at three knots per hour; the wind was blowing towards the west at approximately two meters per second.

While the patient was working on the deck he placed one towel on his head, another towel around his neck. He was wearing a rubber overcoat, a sleeveless undershirt, a cotton fundoshi, cotton underpants, cotton gloves, and long rubber boots to the knees. He was not wearing socks. Around both wrists he had wide (3.0cm) rubber bands. His entire body was soaked with sea water and sweat. He states his body was covered by the falling ash and ^{it} adhered because of the dampness. The ash particles were pencil point in size and rather uniform. Due to irritation his eyes began to smart, then tear, and finally there was pain. He, therefore, covered as much of his face as possible with another towel.

The lines were finally brought in at about 10 a.m. The decks were washed down with sea water. The patient then washed his head and face with sea water and "monogen". Then he went to his bunk, took off his clothes, except for the wrist bands, and slept until 4 p.m. Upon awakening he felt well and was hungry; however, there was a heavy yellow secretion draining from his eyes and his hands were swollen and painful to the exclusion of clenching his fists.

On the morning of March 2 he was only able to open his eyes by pulling the lids apart with his fingers as the lids were matted by the yellow discharge. This matting continued until March 14 when the vessel arrived at the port of Yaizu.

On March 3 during the return trip other members of the crew remarked on a pigmentation of a muddy brown color appearing on the patient's face. At the same time this ~~same~~ discoloration became apparent under the wrist bands. About March 4 his scalp began to itch; upon scratching vesicles appeared over the occipital and left temporal regions, which were tender to touch. The hairs of the scalp began to epilate with little tension. By March 10 there was definite spontaneous epilation though slight.

~~CONFIDENTIAL~~

CONFIDENTIAL

32

~~TOP SECRET~~
- 7 -
his first shave, post-fall out, was on March 7 and was uneventful. On March 8 vesicles appeared around, on, and in both ears.

In an effort to minimize the effect of the ashes he bathed on March 1 with sea water and "Monogen"; on March 3 with tap water and soap; on March 6 with sea water and "monogen"; he trimmed his nails twice while at sea.

On March 14 at 6 a.m. the ship entered Yaizu harbor. He went to his home and bathed with soap and warm water. He then went to the public hospital in Yaizu because of the skin pigmentation, the ear vesiculation, and eye discharge. Because these lesions were more apparent on him and a shipmate, YAMAMOTO, they went to the Tokyo University Hospital. This patient was immediately admitted.

He has never complained of nausea, vomiting, fever, diarrhoea, sore throat, gingival bleeding, or petechiae. He has slept and eaten well.

While at sea his diet consisted of vegetables stocked in Japan and fish from the crews' catch. This included small fish caught on the lines during the fall-out. The diet was supplemented with concentrated vitamin preparations. The fresh water tanks were filled in Japan. These tanks were dumped and re-filled in Yaizu on March 14.

On physical examination there was seen a well developed muscular young Japanese man who appeared older than his stated age. His temperature was 98.8, pulse 72, BP 120/70. There were acneiform lesions on the face, chest, and back. Over the left ear and on the external auditory meatus area there were small vesicles; the skin in these areas was cracked and swollen draining a purulent sanguinous material. Over the rest of the face there was seen desquamation of dark muddy skin leaving what appeared to be a normal pigment layer of skin in view. On the abdomen in the beltline region there were

0.3 to 1.0 cm. slightly raised magenta or purple, circular lesions, which were not tender. The hair on the head was closely cropped and over the cranial vault was seen a large stellate shaped cracking of the skin of the scalp, the center of this star being a lesion approximately three centimeters by two and one half centimeters covered by a raised golden flaked discharge. The branches running out from this center were covered with a similar material. This entire area was tender and boggy. Over the wrists, on both hands, and also at the base of the toenails were small colorless to purple vesicles on a red background. On the base of the left thumb, dorsal surface, there was an ulceration about 2.5 centimeters by 2 centimeters covered by what appeared to be normal granulation tissue. There were many discreet firm nontender lymph nodes in the cervical, axillary, epitrochlear, and inguinal lymphatic chains. The left ear was described above and in the left auditory canal was a purulent sanguinous discharge. The sclerae were muddy. There was a slight injection of the conjunctivae. The fundi revealed increased perivascular sheathing of the arteries. In the nasopharynx there were no petechiae. The tonsils were moderately enlarged. The corners of the mouth were cracked, crusted and bled on slightest touch. On the chest wall at the junction of the sternum and the second rib on the left was a cyst-like mass lying beneath an acne scar. The lungs were clear. The heart was not enlarged. The rate and rhythm were regular. The sounds were of good quality. There was a grade II systolic murmur at the apex and along the left sternal border in the fourth and fifth interspaces. The abdomen was well muscled. The liver was down two finger breadths (3 centimeters) below the costal margin in the mid-clavicular line; it was nontender. The spleen edge could

~~CONFIDENTIAL~~
USIA OR ARCHIVES

~~CONFIDENTIAL~~ ~~CONFIDENTIAL~~
9
just be felt by the finger tips under the left costal margin; it was not tender. On rectal examination no masses were palpable. Anoscopy revealed an internal hemorrhoid and some erosion of the rectal mucosa due to instrumentation. Both hands were markedly swollen and could not be closed. They were not tender. At the base of the right thumbnail, under the nail, was a small hemorrhage. The reflexes were physiological.

Laboratory Reports: See Appendices

YAMAMOTO, Tadashi T-2 (Tokyo Case)

At around 4:00 a.m. of 1 March 1954, this patient who is chief engineer stopped the ship's engine and went up on deck. He immediately noticed clouds on the horizon to the west. He saw no flash, and noticed no luminosity within the clouds. There was no definite mushroom shape to the clouds. Three minutes after arriving on the deck he heard a loud, dull explosion which was immediately followed by two light reports. The patient states that the direction of the flash as seen by others was immediately checked on charts and proved to be in the direction of Bikini; they surmized that this might be an atomic explosion. It was decided to move immediately and the patient went down to the engine room and started the engine. The ship advanced toward the east, and the patient immediately began to help the other members of the crew in raising the fish lines. While he was working on deck the patient noticed that the clouds gradually spread over the sky from the west, until almost the entire sky was covered except in the east, where he could see some clear sky. At about 6:00 a.m., a fine, whitish dust began to settle on the ship, blown in by a very slight wind from the east.

At this time the patient was dressed as follows: heavy cotton cap with brim, cotton undershirt with long sleeves to the wrist, cotton boxer shorts with drawstring, cotton underpants reaching to the ankles, heavy knit cotton socks, heavy rubberized overalls covering the front of the chest and the entire lower half of the body, rubber boots reaching to just below the knees, and cotton gloves. During the period when this dust was falling, the patient was working on deck with the lines and ropes; his clothing and body were wet with sea water; the dust adhered to the patient's hair, face, wrists and clothes. The patient also got dust in his eyes which caused immediate mild smarting. The patient worked in this falling dust for about four hours, from six to ten a.m., during which time he had breakfast under a roof with open sides. He does not believe dust entered the food or the tea which he drank at that meal.

At ten a.m. the work was completed. During this four-hour period the ship had moved almost ten miles to the east. The ship was then put on a course "directly away from Bikini", and after approximately a half hour the ship was out of the dust fall.

In the meantime the patient had removed all of his clothing except for the shorts, and washed his face, hair and hands with sea water from the ship's hose, using "Monogen" (detergent). The patient then put on fresh clothing except for his shorts, which he wore for three more days. After changing his clothes the patient rested in his bunk for about three hours. When he awoke, he felt tired and nauseated and vomited once, bringing up his breakfast. He did not notice any blood or dark material in his vomitus. He felt better after vomiting, but for the rest of the trip, until he landed, he complained of becoming "sea-sick" with mild headache and mild nausea whenever he was in the engine room.

He complained of a yellow, waxy secretion in both eyes, and for a number of days before the ship landed, he complained of slight difficulty in reading gauges in the engine room. The patient washed his eyes with a small amount of fresh water and the secretion lessened before the ship reached Yaizu. There were no bowel changes or urinary complaints during the trip or since arriving in Japan.

On March 2, the patient was told by his shipmates that his face was darker than usual. About one week following exposure to the dust, the patient noticed a small vesicle on the intraphalangeal fold of the fourth and fifth fingers of the right hand. This was neither pimply nor itchy. The patient broke this blister and applied penicillin ointment. His face was seen to become gradually darker. Also, about this time, the patient complained of itching in his left ear which he relieved by scratching with a match. He complained of itchiness and burning on the back of his head and neck where they came into contact with his pillow.

The patient had no other complaints during the trip. He felt well when he was on deck, and had only mild malaise and nausea when down below. The patient had at least two and perhaps three baths before landing, the first on the second day. These were all taken in sea water and "Monogen" was used. The patient also washed his hair on these occasions. The patient did not wear boots or shoes again, going around on deck with "geta" on bare feet. He also wore a cotton shirt and cotton pants. The underwear worn on the day of exposure were washed in sea water on the fourth day and were worn again. Food and water from the ship's store and included fish (tuna) caught on the trip.

The patient sustained a small cut between the fourth and fifth fingers on the right hand from the mouth of the glass "monogen" bottle on the third day. This cut seemed to heal normally.

~~CONFIDENTIAL~~

The ship reached Yaizu at 5:00 a.m. on the fourth of March. The patient went home, took a bath in fresh water, using common toilet soap, and also washed his hair. He then had a haircut (regular long). The patient then went to the Kyoritsu Hospital in Yaizu, together with other shipmates, where he was examined, and medication applied to the ear.

On 15 March the patient was seen in the out-patient clinic of Tokyo University Hospital and was advised to enter the hospital for examination and treatment. He returned to Yaizu that day and returned on 16 March to be admitted, to the Shimizu Surgical Service of Tokyo University Hospital. Since admission the patient has had no complaint except for changes in the skin lesion, with increase in pigmentation, and some spread of the lesions in the hands.

The patient has had daily baths at this hospital, has had his hair cut short and nails trimmed. Several blood counts and bone marrow aspirations have been done. Non-specific medication has been applied to the skin lesions, and the eyes are being treated daily with boric acid solution washings.

On physical examination there was seen a well developed and muscled young Japanese male. His temperature was 99.0, pulse 84, BP 135/60. On the head was a well demarcated area completely around the cranium where his hat had protected his scalp. The unprotected area showed a darkening of the skin with some slight desquamation which revealed what appeared to be a normal pigmented skin. On the back of the neck there was one small discrete pustule. Both ears showed slight swelling with cracking of the skin. In the left ear the skin was eroded and there was a sanguinous purulent discharge; this type discharge was also seen in the left auditory canal. Both hands showed some swelling; however on the palmar surface of the left second, third and fourth fingers, there were huge blisters running the length of the fingers which had a greenish gray hue. Over the beltline

~~CONFIDENTIAL~~
-13-

of the abdomen anteriorly there were seen discrete dark purple circular lesions ranging in size from 2 millimeters to approximately 1 centimeter which were nontender. There were discrete nontender nodes in the cervical, axillary, and inguinal lymphatic chains. The eyes were clear and showed no signs of inflammation or discharge. The fundi were not remarkable. The nasopharynx showed no ulceration or gingival bleeding. The pharynx was slightly reddened. The lungs were clear, the heart was not enlarged. The sounds were of good quality. The rate and rhythm were regular. There were no murmurs. The abdomen was well muscled. The liver edge was palpable 2 centimeters below the costal margin; it had a sharp edge, felt soft, but was not tender. The spleen edge was just palpable to the fingertips and was not tender. Rectal examination revealed no masses. On anoscopy there were seen some erosions from instrumentation but no other bleeding points. The reflexes were physiological.

Laboratory Work: See Appendices

YAIZU CASES

ANDO, Saburo (T-3)

On March 1, 1954, this 29 year old fisherman saw a flash followed by three reports. The captain of the ship ordered the lines on board and the patient worked wearing rubber pants, a shirt, rubber sleeves, cotton gloves, a straw hat. About 2½ hours later a fine ash began to rain down on the ship. By 11:30 a.m. the lines were reeled aboard. The patient removed his shirt and pants, washed his hands and face with sea water and soap, and went to bed. On awakening he cleaned ropes which were coated with ashes.

During the return trip to Yaizu he bathed twice with tap water and soap, and two to three times with sea water and "Konogen".

Following the exposure to dust there was eye pain, tearing, and a heavy yellow

~~CONFIDENTIAL~~

CONFIDENTIAL

~~CONFIDENTIAL~~ ~~CONFIDENTIAL~~
-14-
discharge which increased until March 14 and then gradually subsided.

Four to five days after exposure he was told his skin was pigmented a muddy brown color. This is still evident. About the same time he had nausea and vomiting. There was never any diarrhea, constipation, fever, gingival bleeding, petechiae or purpura.

While aboard ship he trimmed his nails once; after reaching port - three times.

On March 15, he entered the hospital in Yaizu because of the pigmentation and eye pain, and swelling of the skin around the mouth, over the wrist and right index finger accompanied by itching and pain.

On physical examination there was seen a well developed and muscled Japanese man. Around the mouth, over both wrists, on the fingers, and on the anterior and posterior aspects of the neck there was seen erythematous and vesiculated lesions. The anterior cervical, axillary, inguinal nodes were enlarged, firm, and nontender. The ears, particularly on the left side, showed the cracking and swelling of the epithelium. The eyes were clear and showed no evidence of inflammation or discharge. The fundi were clear. The nasopharynx showed no ulcerations or gingival bleeding. The heart and lungs were clear. In the abdomen there were no organs or masses palpable. There were no areas of tenderness.

Laboratory Work: See Appendix

HATTORI, Takeji (T-5)

This 36-year old fisherman was exposed at the same time as the other crew members. He was dressed with a cotton shirt, cotton pants, cotton shorts, cotton socks, and rubber boots. (He had no rubber overalls.) He had wrapped around his head a towel which left the top of his head uncovered.

During the fallout he was on the outdeck of the ship except for a meal.

~~CONFIDENTIAL~~

US DOE ARCHIVES

worked on deck throughout the fallout. Afterwards he changed his clothes completely but did not wash himself except for his face. On the following day he developed a mild headache, mild malaise and occasional mild nausea. There was no vomiting and no diarrhea. The patient noticed epilation for the first time on March 20.

This patient took a bath and washed himself thoroughly on the second day after the fallout. He had a hair cut on the 17th of March at which time he trimmed his nails.

Physical examination revealed a well muscled, well developed young Japanese man. Over the entire left ear and on the anterior and posterior neck areas were erythematous and vesiculated lesions. The anterior cervical, axillary, and inguinal nodes were enlarged bilaterally but were nontender. The eyes were clear with no tearing or signs of inflammation. The fundi were clear. The nasol pharynx showed no gingival bleeding and there were no ulcerations. The heart and lungs were clear. In the abdomen no masses or organs were palpable. There was no tenderness.

Laboratory Work: See Appendix

SAITO, Akira (T-18)

This 25-year old Japanese fisherman at the time of the fallout was wearing a short-sleeved cotton short, a long-sleeved thin cotton shirt, shorts, and cotton pants. Over all were the rubberized fisherman's tunic. On his feet he had cotton socks and rubber boots. For the first two hours he wore a cotton cap but then replaced it with a ~~xxx~~^{wrapped-}around towel. During the dust fallout his eyes began to smart and subsequently there was pain. For two or three days he experienced malaise, slight loss of appetite, and mild nausea but no vomiting. When the crew's work was finished during the fallout, he changed clothes and only washed his face. The following day he took a bath; while bathing he washed himself thoroughly and repeated

this process once more before leaving the ship. On March 17th his hair was cut and his nails were trimmed. The third day after the ash shower he began to notice darkening of his skin. About March 10 lesions consisting of erythematous and vesiculated areas appeared on the hands, wrists, ears, and portions of the neck. He noticed epilation for the first time on March 9. At no time did he complain of oropharyngeal lesions, diarrhea, petechia or purpura.

Physical examination revealed a well developed well nourished young Japanese male. Over both ears, around the entire neck and palmar surfaces, of both hands were vesiculated lesions, some desquamating. There was lymphadenopathy along the posterior cervical chains in the axillary areas and inguinal regions. A right supra clavicular node was also palpable. None of these nodes were tender. The eyes were clear and showed no signs of inflammation or thick discharge. The fundi were not remarkable. The nasal pharynx showed no evidence of ulceration or gingival bleeding. The heart and lungs were clear. In the abdomen the liver and spleen were not palpable. There were no other masses.

Laboratory Work: See Appendix

SUZUKI, Shinzo (T-19)

This 29-year old Japanese male fisherman on the morning of March 1 was on deck when he saw a flash on the western horizon. He was working on the deck when a fine ash shower began a few hours later. At that time he was wearing a white cotton shirt, a cotton hat, cotton gloves, rubberized fishing pants, and high rubber boots. Following work he went to his bunk and stripped of his shirt and proceeded to wash only his face and hands. Subsequently, however, he washed his entire body five times with tap water and "Monogen". Following his exposure his eyes began to secrete a thick yellow discharge. His skin became a dark mud color.

Four days after the fallout, both ears and the occipital region began to itch. Because of this he cut his hair to a short length and found these areas covered with vesicles. The occipital area showed epilation later.

On the first day following the fallout he complained of a headache. He had no appetite and occasionally felt nauseated. On March 4 he vomited one time. This made him feel better and by March 10 he states he felt well. The epilated area of the scalp increased in size. On March 15 he noticed pain in his finger joints and over these joints there was a black brown pigmentation. The hands and fingers showed a localized warmth. He remembers no diarrhea, no fever, no petechia and no purpura.

On physical examination there was seen a young well developed muscled Japanese man. On both ears, on the posterior aspect of the neck, on the occipital area and on the entire hands there were small vesicles and small areas of erythema and desquamation. The scalp was epilated on the occipital region. The axillary and inguinal nodes were enlarged bilaterally. There were several right supraclavicular nodes. None of the nodes were tender. The eyes were clear and showed no inflammation or yellow discharge. The fundi were abnormal in that the arteries showed marked perivascular sheathing. The oropharynx showed no ulcerations or evidence of gingival bleeding. The heart and lungs were clear. In the abdomen there were no organs or masses palpable. There was no tenderness.

Laboratory Work: See Appendix

TAKAKI, Kaneshige (T-21)

This 30-year old Japanese fisherman was on the deck when he saw a flash in a westerly direction. This flash was followed by a loud report. He began to help other members of the crew working on the deck. He went below to the crew's quarters and while there the ash began to fall on the ship. After resting for two hours he

34

windows because the dust was causing smarting of his eyes. Thereafter the pilot-house was comparatively clear. Approximately one hour later he went down to the deck to help his crew reel in the lines. He was wearing a three-quarter sleeved cotton shirt, a wide-brimmed hat, rubber overalls, cotton socks, and knee-length rubber boots. He stayed on the deck until the ship left the dust area. Thereafter he washed his face only with seawater from the ship's hose. His eyes continued to smart until the next day when a particle of dust was removed from his left eye. He had no similar complaints subsequently. At no time did he have a sore throat. However, he did have mild headache, slight malaise, and a slight loss of appetite for two to three days.

About the 7th or 8th of March his skin began to smart around the abdomen. It reddened and then darkened. Recently, this skin area peeled. At the same time a similar course of events was occurring on the wrists. On the tenth of March the ears and back of the neck began to itch. At the time of questioning he did not feel ill. On the 17th of March he had his hair cut and the nails trimmed.

While on the return trip to port he had a total of four showers using seawater and "Monogen".

On physical examination there was seen a well developed muscled young Japanese man. On both ears, around the entire neck, over the mid-abdomen, on both hands, were areas of erythema and vesiculation. On the anterior lower aspect of the neck and in the area of the beltline anteriorly were small discrete very slightly raised dark purple lesions varying in size from 3 millimeters to 1 centimeter. The axillary nodes were discretely palpable bilaterally and were nontender. The eyes showed no evidence of inflammation or discharge. The fundi were clear. In the nasal pharynx there were no ulcerations or gingival bleeding. The heart and lungs were clear. In the abdomen there were no palpable organs or masses. There was no tenderness.

US DOE ARCHIVES ~~FOR OFFICIAL USE ONLY~~

Radiation Signs and Symptoms of All Patients

Unit No.	Malaise	Nausea	Diar-rhea	Fever	Vomit-ing	Oro-pharyngeal Lesions	Purpura	Epilation
T-1	*							+
2	*	+	+					+
3	*		+		+			+
4			+		-			+
5	+							+
6		0						
7		0						
8		0						
9								+
10		0						
11		0						
12		0						
13		0						
14		0						
15								+
16	*	+	+		-			+
17		0						
18		+	+		-			+
19	*	+	+		+			+
20								+
21	*	0	0	0	0		0	+
22		+						+
23								+

~~CONFIDENTIAL~~

~~CONFIDENTIAL~~

	Increased Pigmentation	Loss Appetite	Fing ^{er} s	Skin Lesions Vesiculation	Eye Signs	Purpura - like Lesions
T-1	+					
2	+					
3	+	+		+	+	+
4	+	+		+	+	+
5				+	+	
6	0			+		+
7	0				+	+
8						
9						
10	0					
11				+		
12						
13	0					
14						
15						
16						
17				+		
18				+		
19	+				+	
20		+		+	+	
21	+			+	+	
22	+			+		
23		+		+	0	
			+	+	+	
					+	

US DOE ARCHIVES

On March 19, 1954, patients Masuda Sanjiro (T-1) and Yamamoto Tadashi (T-2) were seen in Tokyo University Hospital and blood counts were performed by Dr. Sears, and Miss Tsuchitori, ^{ABCC} chief hematology technician. Blood smears were made and will be examined after staining at ABCC in Hiroshima. Bone marrow specimens were obtained 16 March 1954 from these two patients by Dr. Miyoshi ^{of Tokyo University} and one unstained slide of marrow from each patient was given to ABCC. These will be examined after staining in Hiroshima. Dr. Miyoshi also had stained slides of marrow from patients Masuda Sanjiro and Yamamoto Tadashi. These were examined 19 March 1954 by Dr. Sears but conditions were such that only low power lens of microscope could be used. No abnormality of either marrow was observed under these circumstances.

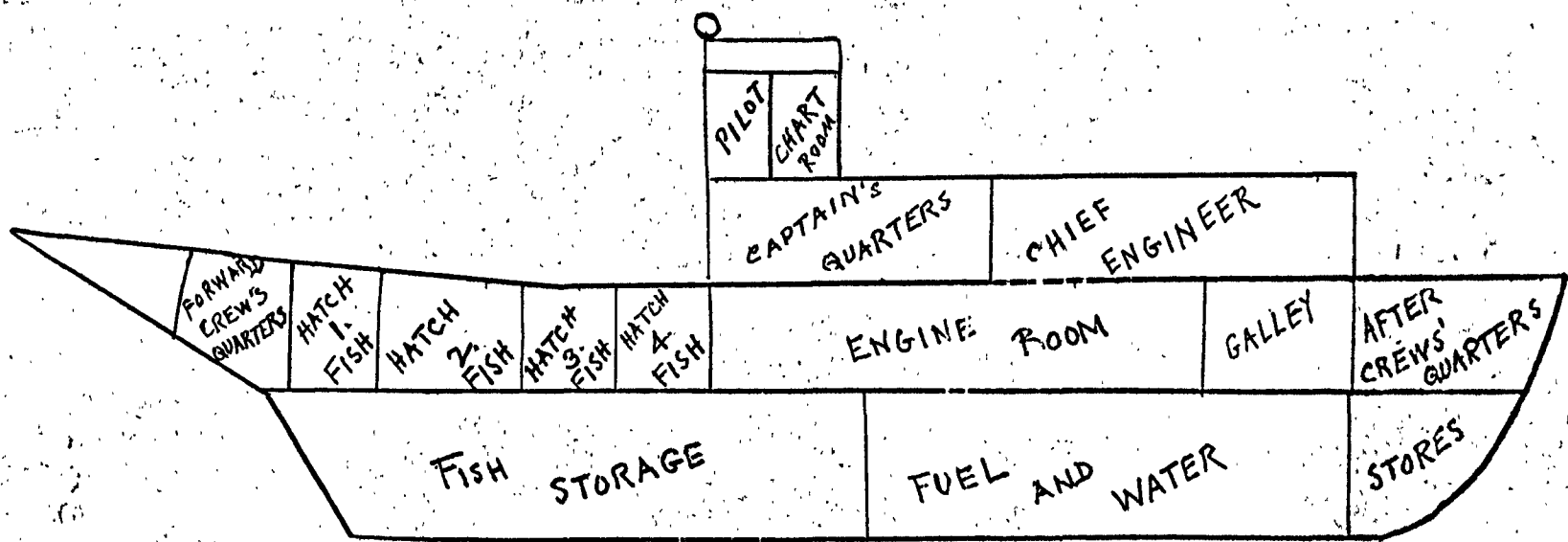
Reports of blood counts on Masuda Sanjiro and Yamamoto Tadashi performed by Yaizu and Tokyo University Hospitals are tabulated below as well as the counts performed by ABCC members.

20 March 1954 - The 21 patients at Yaizu were visited but ABCC staff were not permitted to obtain any blood or bone marrow specimens. Reports of blood counts performed by Yaizu staff are tabulated below.

Blood slides had been made 17 March 1954 on all patients and sent to Tokyo University Hospital. On 22 March 1954 these slides were examined by Dr. Sears and Miss Tsuchitori. Differential count of 100 cells was performed on each specimen as well as a thorough low power lens study. In general, these blood smears, while adequate, were not of the quality considered desirable by ABCC. The smears were made on glass slides rather than cover slips and the latter method is considered to give greater accuracy. There was distortion of many white blood cells so that identification was rendered difficult. The stain was lighter than that used by ABCC and recognition of platelets was especially unsatisfactory. However, a general impression of white blood cell distribution, and red blood cell and platelet appearance could be obtained and these are tabulated below. There was satisfactory agreement between reported white blood counts and appearance of white cells on slides; i.e., there was an abundance of cells on stained slides whose reported counts were normal or slightly elevated and an apparent paucity of cells on the slide from Misaki Yoshio (T-16) whose reported white cell count was 2900 on 17 March 1954. The blood slide from Suzuki Shinzo (T-19) had apparently become damaged and only a small portion of the material remained. Red cells and platelets could not be observed satisfactorily. The patient appears to have a definitely

- 37 -

FOR OFFICIAL USE ONLY



100 TON SHIP
" FUKURYU MARU "

abnormal White cell differential count and should have further very careful study.

Bone marrow specimens were obtained 16 or 17 March 1954 by Dr. Miyoshi from 4 Yaizu patients, Ando Saburo (T-3), Misaki Yoshio (T-16), Suzuki Shinzo (T-19) and Takaki Kaneshigo (T-21). A stained slide of each marrow was examined 22 March 1954 by Dr. Sears. These smears were also made on glass slides rather than cover slips and demonstrated much cell distortion so that an accurate count was impossible to perform. Again only general impressions could be obtained and these are discussed below.

Bone marrow "counts" are reported by the staff at Tokyo University. It has not been our practice to perform total "counts" on bone marrow as their value is considered highly questionable because of the heterogeneous nature of bone marrow specimens.

HEMATOLOGY

Tokyo Patient

YAMAMOTO, Tadashi

T-2

MARCH

	14	16	17	18	19	20	21	22	23	24	25
White Blood Cells	5000	6800	7400	4000	4400	5300	5700	4360	2910	4050	3410
Lymphocytes		13	14.5		12	16	24	15.5	13.5	16	
Segmented		75	56		76.5	75	59	71.5	64	67.5	
Banded ^s		9	10.5		1.0	3.5	4	3.5	8.0	7.0	
Monocytes		3	18		7.0	1.0	7	8.5	11	8	
Eosinophiles		0	0.5		1	0.5	5	1.5	3.1	1	
Basophiles					1.5	0	1	0.5	0	0	
R ⁺ Blood Cells					4.0	4.0	4.6	4.0	4.3	4.1	5.0
Hemoglobin %					85	85	93	105		112	102
Hematocrit					39	44	48.8				
Whole Blood Specific Gravity					1.055	1.055		1.057			
Plasma Specific Gravity					1.030	1.026		1.027			

Tokyo Patients

~~FOR OFFICIAL USE ONLY~~

Cells	Masuda	Yamamoto
	T-1	T-2
Cell count	66,000	48,000
Myeloblast	0.8	0.8
Promyelocyte	4.0	4.0
N. myelocyte	5.4	7.6
metamyelocyte	6.6	11.0
band	14.4	9.2
seg.	23.4	20.4
E. myelocyte	0.8	
metamyelocyte	1.0	
band	0.4	0.2
seg	1.8	0.8
Baso	0.2	
Lymphocytes	9.0	5.4
Monocytes	2.4	15.6
Plasma	1.2	3.4
Proerythroblast	0.2	
Macro - baso	0.4	0.8
poly		4.4
Micro - baso	7.4	
poly	11.0	
ortho	6.0	
}	24.4	
Nor - poly		6.2
ortho		7.2
Reticulum	2.2	3.0
mitosis cell	1/500	

US DOE ARCHIVES

STATUS VERIFIED UNCL

BY Gene Hays DATE 3/24/81

NON-CCRP

53

White Blood Cell Counts on YAIZU Patients

<u>File No.</u>		<u>March 14</u>	<u>March 16</u>	<u>March 17</u>
		<u>Most Severe*</u>		
T-3	ANDC, Saburo		3,800	8,700
T-16	MISAKI, Yoshio		4,300	2,900
T-19	SUZUKI, Shinzo		3,600	6,300
T-21	TAKAKI, Kaneshiga		3,100	5,100
		<u>Less Severe</u>		
T-4	HANDA, Shiro	5,100	5,200	6,500
T-5	HATTORI, Takeji	5,900	6,400	7,300
T-6	HIRAI, Isamu	6,700	5,800	7,200
T-7	HOSONE, Hisao	5,600		7,700
T-8	IKEDA, Masaho		6,200	7,000
T-9	KAWASHIMA, Masayoshi	6,600	5,600	6,800
T-10	KOZUKA, Hiroshi		7,900	6,000
T-11	KUBOYAMA, Aikichi		7,200	6,900
T-12	KUBOYAMA, Shiro		6,000	5,700
T-13	MASUDA, Kyonosuki		6,800	8,000
T-14	MASUDA, Yuichi	6,100	6,000	9,400
T-15	MISAKI, Susumu		6,300	7,100
T-17	OISHI, Matashichi		4,100	5,000
T-18	SAITO, Akira	5,200	5,000	9,300
T-20	SUZUKI, Takashi		4,800	8,700
T-22	TSUTSUI, Hisakichi			7,500
T-23	YOSHIDA, Katsuo		6,200	9,000

* Count below 4,000 wbc per cu. ml. blood.

STATUS VERIFIED

UNCL

NON-CCRP

BY

Jace Diaz

DATE

3/24/81

31
54

Yaiizu patients

~~TOP SECRET~~

	Seg	Band	Lgm	MON	EOS	Other Cells	WBC	RBC	Platelets
T-3 Ando	71	8	21	-	-	-	N	N	N
T-16 Misaki (Y)	60	7	28	2	3	-	Reduced	N	Appear decrease
T-19 Suzuki Shinzo	38	38	21	1	1	Juv 1	"Toxic" left Shift		Not report-able. Poor slide
T-21 Takaki Koneshigo	58	6	26	2	8	-	N	N	Appear decreased
T-4 Handa	67	4	26	2		Turk 1	N	⁺ hypochromia	N
T-5 Hattori Takaji	65	6	25	2	1	Bqso 1	N	N	N
T-6 Hirai	71	4	19	0	6	-	N	N	N
T-7 Hosone Hisao	59	3	27	2	9	-	N	N	N
T-8 Ikeda	67	12	16	4	1	-	N	N	N
T-9 Kawashima	68	11	18	2	1	-	N	N	N
T-10 Kozuka	55	7	37	-	1	-	N	N	N
T-11 Kuboyama	61	4	28	5	1	EOS Bond 1	N	N	Appear decreased
T-12 Kuboyama (S)	70	8	17	2	3	-	N	N	appear decrease
T-13 Masuda (K)	65	1	24	3	7	-	N	N	N
T-14 Masuda (Y)	60	0	34	0	6	-	N	N	N
T-15 Misaki (S)	69	3	24	3	1	-	N	N	N
T-17 Ofshi	61	3	30	4	2	-	N	N	N
T-18 Saito	62	4	28	1	5	-	N	N	N
T-20 Suzuki Takashi	76	3	21	-	-	-	N	N	N
T-22 Tsutsui (capt)	67	5	26	2	-	-	N	N	N
T 3 Yoshida	70	7	21	0	2	-	N	N	N

~~TOP SECRET~~

N = normal appearance

17

~~CONFIDENTIAL US ONLY~~

~~CONFIDENTIAL US ONLY~~

W.B.C.

in million
R.B.C.

HGB

14 Mar

16 Mar

17 Mar

17 Mar

17 Mar

	14 Mar	16 Mar	17 Mar	17 Mar	HGB
T-3 Ando Saburo		3800	8700	5.21	98%
T-16 Misaki Yoshio		4300	2900	3.08	
T-19 Suzuki Shinzo		3600	6300	4.04	73%
T-21 Takaki Kaneshiga		3100	5100	3.65	89%
T-4 Handa Shiro	5100	5200	6500	4.76	
T-5 Hattori Takeji	5900	6400	7300	3.96	
T-6 Hirai Isamu	6700	5800	7200	4.36	
T-7 Hosone Hisao	5600		7700	5.30	
T-8 Ikeda Masaho		6200	7000	3.96	
T-9 Kawashima (Masayoshi)	6600	5600	6800	4.24	
T-10 Kozuka Hiroshi		7900	6000	4.53	
T-11 Kuboyama (Aikichi)		7200	6900	3.87	
T-12 Kuboyama Shiro		6000	5700	4.30	
T-13 Masuda Kyonosuke		6800	8000	5.02	
T-14 Masuda Yuichi	6100	6000	9400	5.50	
T-15 Misaki Susomo		6300	7100	4.08	
T-17 Oishi Matashichi		4100	5000	4.43	
T-18 Saito Akira	5200	5000	9300	4.01	
T-20 Suzuki Takashi		4800	8700	4.71	
T-22 Tsutsui Hisakichi			7500	4.45	
T-23 Yoshida Katsuo		6200	9000	4.35	

~~CONFIDENTIAL US ONLY~~

Yaizu Patients

? 16 March 1954
? 17

Ando Saburo (T-3)

Count 157,000

Erythroid elements appear normal except for possible slight increase in mitotic forms, Myeloid elements - Neutrophilic series appears normal.

There is a moderate increase in eosinophilic cells.

Occasional Plasma cell present

Megakaryocytes appear abundant.

Misaki Yoshio (T-16)

Count 67,000

Erythroid elements appear normal. Myeloid series shows slight decrease in young forms. No increase in eosinophilic cells noted.

Occasional megakaryocyte present.

Suzuki Shinzo (T-19)

Count 52,500

Erythroid elements appear normal.

Myeloid series appears normal - no increase in eosinophilic cells.

Moderate number of plasma cells present.

Megokaryocytes appear decreased - only rare one seen.

Takaki Kaneshiga (T-21)

Count 19,000

Erythroid elements appear normal.

Myeloid series appears normal - no increase in eosinophic cells or plasma cells noted.

Megakaryocytes appear decreased - only rare one seen

Radioactivity Survey

(Milliroentgens per hour)

Tokyo Patient

MASUDA, Sanjiro

T-1.



Survey - meter counter

Distance: 5 cm

Region	16 March	17 March	18* March	18** March
Parietal	9.0	Hair Cut,	2.0	2.0
Frontal	1.8	Head washed with soap	0.2	0.2
Temporal, right	1.0		0.3	0.2
Temporal, left	3.8		1.0	0.8
Occipital	3.8		1.0	0.5
Lips	0.5		0	0
Right ear	1.0		0.5	0.3
Left ear	1.0		0.5	0.4
Chin	1.0		0.5	0.4

* Before Washing

** After Washing



RADIOACTIVITY SURVEY


(Counts per Minute)

Tokyo Patient

MASUDA, Sanjiro

T-1

Region	18 March	19 March	20 March	22 March
Parietal	694	652	503	356
Frontal	169	213	93	35
Occipital	455	263	217	251
Left Temporal	248	219	215	66
Right Temporal	206	175	128	69
Chin	188	182	135	85
Left Hand, dorsum	57	59	26	24
Right Hand, dorsum	36	44	18	12
Left plantar surface	38	66	20	9
Right plantar surface	77	24	28	7
Nails, left hand			204	



~~CONFIDENTIAL USE ONLY~~

Radioactivity Survey

(Milliroentgens per hour)

Tokyo Patient

YAMAMOTO, Tadoshi

T-2

Region	16 March	17 March	18* March	18** March
Parietal	1.8	Haircut; Head washed with soap	0.2	0.1
Frontal	0.6		0	0
Occipital	1.0		0.4	0.1
Temporal, right	1.3		0.3	0.1
Temporal, left	3.0		0.8	0.3
Lips	0.2		0	0
Right ear	0.4		0.3	0.1
Left ear	3.0		0.8	0.3
Nuchal	0.4		0.4	0.1

* Before washing

** After washing

~~CONFIDENTIAL~~
Radioactivity Survey
(Counts per minute)

Tokyo Patient

YAMAMOTO, Tadashi

T-2

Region	18* March	19 March	20 March	22 March
Parietal	208	199	121	57
Frontal	123	420	61	25
Occipital	330	234	186	74
Temporal, Left	413	268	97	45
Temporal, Right	211	168	99	27
Nuchal	217	254	130	28
Left hand, dorsum	188	47	103	8
Right hand, dorsum	141	50	63	21
Left plantar surface	129	23	29	4
Right plantar surface	130	26	32	12

* After haircut

~~CONFIDENTIAL~~

THE SHIP

The Fukuryu Maru No. 5 is a vessel of unknown age. It was captured by the Indonesians in World War II, which implies at least 13 years of sea voyages. The Fukuryu Maru is 99.9 tons. It follows somewhat the general plans for tunny boats built at the Yaizu shipyards, differing from the usual vessel in being about 50 tons lighter.

The vessel was monitored on at least three different occasions. The Tokyo University group headed by Drs Nakaidzumi and Kakehi generously gave ABCC their figures for March 17 and 20 (see Appendix). An American team from the United States Air Force visited the ship on 20 March and took a few readings given below.

" A. Average overall level of radiation from boat is about 20 mr per hour.

Radiation is gamma.

B. Crew quarters 35 mr

C. Open deck 8 mr

D. Covered passageways 12 mr

Value of 50 R as minimum accumulated dosage for crew members still appears reasonable."

From: Dr. I. ZHI, Dr. NAKHIDZUMI

Tracerlab

Model SUIE Se. #484

Bakelite

Aluminum Foil

Ship's Area	17 March 1954 1500 hours		20 March 1954	
	Gamma	Gamma plus beta	Gamma	Gamma plus beta
Afterdeck	20 mr/hr	30 mr/hr	21	23
Port side				
Under bridge	42	48	32	33
Above hatch at 3rd hold	8	10	7	7
Forward crew space	12	14	14	14
Wireless room	14	18		
Metal grating over engine room	20	20	18	18
Ceiling of engine room	30	32	20	20
After crew space	60	80	72	72
Ceiling of after crew space	95	100	90	92
After upper deck	100	110		
Captain's cabin	45	45		
Wheel house	30	32	26	27
Rope on after upper deck	80	95	75	80
Bilge at 4th hold	10	10	5	6

SUGGESTIONS:

~~TOP SECRET - NOE ONLY~~



Move all patients to Tokyo and place in one hospital.

Reason: Expert care - more likely to be experts in large center.

Time saving - for physicians caring for patients

- saves long train or auto ride to Yaizu

Prevention - Late developments by better care.

Thoroughdaily check of all patients.

Decontaminate by detergents - hair and nails.

Shave heads of all patients who show activity by geiger counter.

Have expert manicuring of nails of all patients who show activity by geiger counter.
(Manicurists and barbers to use gloves on own hands)

Diet study - Sailors may have had inadequate diet

-correct deficiencies - vitamins, etc.

- high protein diet.

Antibiotics - to control infections. (Every other week use penicillin and streptomycin, alternate with terramycin, aureomycin, "sulfas"

Chelating agents with increased mineral intake (acid diet and calcium).

Scintillation counters - several needed. Three (only) in Japan. To monitor thyroid and lymphnode areas, mediastinum and neck. (To monitor fishing fleet at five ports.

To monitor bone ends - sternum and ribs.

To monitor kidney and bladder areas.

To monitor liver.

All excreta, expired air, hair, etc.

Treat all patients as if the worst kind of bomb had been used.

~~TOP SECRET - NOE ONLY~~

65