


*Sipe*

401042

# NAVAL MEDICAL RESEARCH INSTITUTE

*R*



SKIN LESIONS, EPILATION AND NAIL PIGMENTATION IN MARSHALLESE  
AND AMERICANS ACCIDENTALLY CONTAMINATED  
WITH RADIOACTIVE FALLOUT

REPOSITORY BNL Records

RESEARCH REPORT  
Project NM 006 012.04.82

COLLECTION Marshall Island

BOX No. MMRD Dept. Office (rm 5-134)

FOLDER NIA  
5007625

The Medical Research Center  
Brookhaven National Laboratory  
Upton, L. I., New York

SKIN LESIONS, EPILATION AND NAIL PIGMENTATION IN MARSHALLESE  
AND AMERICANS ACCIDENTALLY CONTAMINATED  
WITH RADIOACTIVE FALLOUT

ROBERT A. CONARD  
Commander, MC, USN

NAHUM R. SHULMAN  
LT, MC, USN

DAVID A. WOOD  
Director, Cancer Research Institute  
University of California Medical Center  
San Francisco, California

CHARLES L. DUNHAM  
Director  
Division of Biology and Medicine  
Atomic Energy Commission  
Washington, D. C.

EDWARD L. ALPEN  
U.S. Naval Radiological Defense Laboratory  
San Francisco, California

L. EUGENE BROWNING  
Lieutenant Colonel, MC, USA  
U.S. Armed Forces Special Weapons Project  
Pentagon  
Washington, D. C.

Vol. 13

pp. 423-450

RESEARCH REPORT  
Project NM 006 012.04.82

NAVAL MEDICAL RESEARCH INSTITUTE  
NATIONAL NAVAL MEDICAL CENTER  
BETHESDA, MARYLAND  
and  
U. S. NAVAL RADIOLOGICAL DEFENSE LABORATORY  
SAN FRANCISCO, CALIFORNIA  
29 August 1955

## ABSTRACT

Following the detonation of a thermonuclear device in the Marshall Islands in the Spring of 1954 a significant amount of radioactive fallout material was deposited on neighboring Pacific islands. Of the 239 Marshallese people and 28 Americans exposed, 64 Marshallese on the island of Rongelap received the highest dose of whole-body penetrating radiation (an estimated 175 r), the most extensive epilation and beta lesions of the skin, and small amounts of internal absorption of radioactive materials. Other island groups were less heavily irradiated. This report is concerned with the epilation and beta lesions which occurred.

Many individuals in the higher exposure groups complained of burning and itching of the skin during the first 24 to 48 hours after exposure. Epilation and skin lesions were observed, beginning approximately two to three weeks after exposure, on skin areas contaminated with fallout. Bluish-brown pigmentation of the fingernails was also a common finding. No primary or secondary erythema was observed and consistently the first evidence of skin damage was increased pigmentation in the form of dark brown to black macules, papules, and raised plaques. The lesions developed largely on the exposed parts of the body not protected by clothing, and occurred usually in the following order; scalp (with epilation), neck, axillae, antecubital fossae, feet, limbs, and trunk. Epilation and lesions of the scalp, neck, and foot (dorsal surface) were the most common. The majority of lesions were superficial without vesicle formation, and after simple dry desquamation healed and repigmented. Approximately 20 percent of the people in the highest exposure group developed deeper lesions, usually occurring on the feet or neck and were characterized by wet desquamation with ulceration, mild burning, itching, and pain accompanied the lesions. The majority healed rapidly with nonspecific therapy. Residual pigment aberration consisting of hyperpigmentation and lack of repigmentation and mild atrophic changes were noted in some deeper healed lesions at six months and one year. Regrowth of hair, normal in color and texture, began about nine weeks post-exposure and was complete at six months. Biopsies of typical lesions at three to six weeks showed changes consistent with radiation damage with marked epidermal damage and much less severe dermal damage. Biopsies at six months showed only a few residual changes. The nail discoloration had "grown out" completely at six months in all but a few individuals.

Submitted by authors 16 February 1955.

Issued by The Naval Medical Research Institute

For Official Use

## INTRODUCTION

Between approximately 5 and 10 hours after detonation of a thermonuclear device in the Marshall Islands in the spring of 1954, a significant amount of radioactive fallout was deposited on neighboring Pacific islands. Exposure to fallout of personnel living on four of these islands resulted in whole-body radiation from gamma rays, skin lesions and epilation largely from beta irradiation, and a minimal amount of internal radiation. This report is concerned with the effects of fallout on the skin and its appendages.

On the most heavily contaminated island the fallout was described as a powdery material, "snowlike," which fell over a period of several hours and whitened the hair and adhered to the skin. Less striking fallout described as "mist-like" was observed on two other islands. Fallout was not visible on still another island which was contaminated to only a mild degree. The severity of the skin manifestations was roughly proportional to the amount of fallout observed. The composition of the four island groups and incidence of skin lesions were as follows:

<u>Group</u>	<u>Composition</u>	<u>Fallout Observed</u>	<u>Extensiveness of Skin Lesions and Epilation</u>
Rongelap	64 Marshallese	Heavy (snow-like)	Extensive
Ailingnae	18 Marshallese	Moderate (mist-like)	Less Extensive
Rongerik	23 White Americans 5 Negro Americans	Moderate (mist-like)	Slight
Utirik	157 Marshallese	None	No Beta Lesions or Epilation

Evacuation of exposed personnel to Kwajalein where medical facilities were available, was accomplished one to two days after the event. It was not until this time that thorough decontamination of the skin was possible.

Skin examinations were carried out almost daily during the first 11 weeks and then again at 6 months and 1 year after the accident. Examinations of unexposed Americans and native personnel were also carried out for comparative purposes. Color photographs and biopsies of lesions in various stages of development were taken.

## SIGNS AND SYMPTOMS

During the first 24-48 hours after exposure, about 25 percent of the Marshallese in the two higher exposure groups experienced itching and burning sensation of the skin and a few also complained of burning of the eyes with lachrymation. Those symptoms were present to a much lesser extent in the Americans on Rongerik atoll who were aware of the danger, took shelter in their butler-type buildings and bathed and changed clothes. These precautions greatly reduced the subsequent development of skin lesions in this group. The people on Utirik, the furthest group away from the detonation, suffered no early skin symptoms. By the time of evacuation, one to two days after the event, all symptomatology subsided. On arrival of an emergency medical team on the ninth post-exposure day, the exposed personnel all appeared to be in relatively good health with no unusual findings on skin examinations. The only evidence of radiation injury was significant depression of peripheral blood elements. However, further evidence of radiation injury became apparent about two weeks after the accident when epilation and skin lesions began developing.

Erythema of the skin was not observed either during the early examinations when a primary erythema might be expected, or later when a secondary erythema might be expected.

After subsidence of the initial skin symptoms there were no further symptoms referable to the skin until the gross beta lesions developed. During the early stages of developing

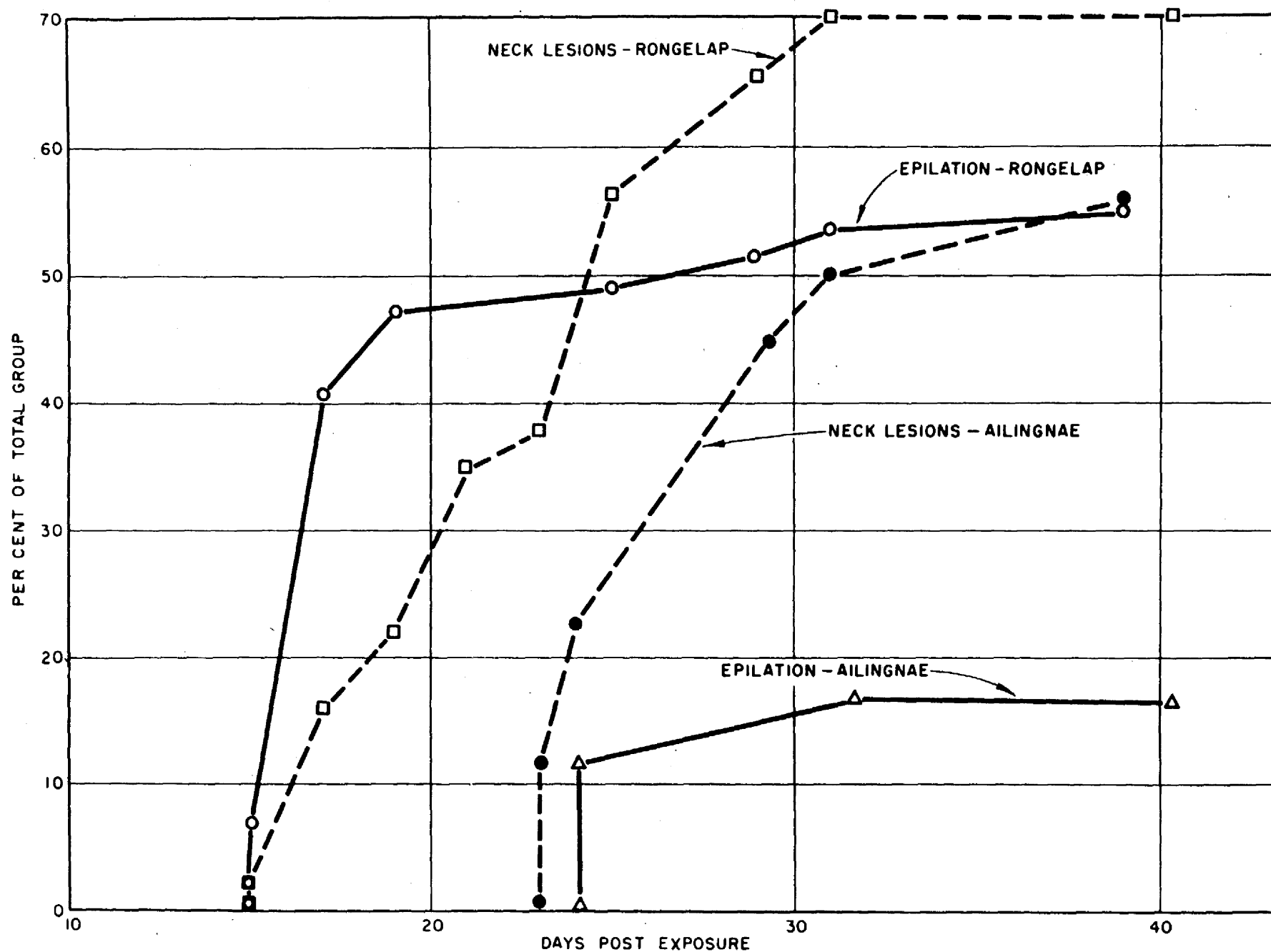


Figure 1. - Comparison of the Incidence and Time of Appearance of Epilation and Neck Lesions in the Rongelap and Ailingnae Groups.

lesions only itching, burning sensation and slight pain were experienced with the more superficial lesions. With deeper lesions more severe pain was experienced. The deeper foot lesions were the most painful and caused some of the people to walk around on their heels for several days during the acute stages. Some of the more severe lesions of the neck and axilla were painful when turning the head or raising the arms. There were no constitutional symptoms associated with the lesions.

## DESCRIPTION OF LESIONS

### 1. Skin lesions\*

#### a. Gross

The time of appearance and severity of lesions varied with the degree of skin exposure in the different groups. The Rongelap group which showed greatest radioactive contamination of the skin (according to instrument readings) were first to develop lesions and epilation at about 12-14 days after the accident. They also suffered the most severe lesions. The lesser exposed Ailingnae and Rongerik groups lagged about a week behind in development of lesions which were less severe and extensive. The Utirik group did not develop any lesions which could be attributed to irradiation of the skin. The relative severity of lesions in the different groups is apparent from the fact that 20 percent of the Rongelap people developed ulcerating lesions while only 5 percent of the Ailingnae and none of the Rongerik people developed lesions of this severity. Ninety percent of the people of Rongelap and Ailingnae developed lesions, compared with only forty percent of the Rongerik group. The lesions were not nearly so extensive on an individual basis in the Ailingnae or Rongerik groups as in the Rongelap group. A comparison of the incidence and time of appearance of epilation and neck lesions in the two groups is illustrated graphically in figure 1.

Nearly all the lesions were spotty and developed on exposed parts of the body not covered by clothing during the fallout. The majority of individuals developed multiple lesions (particularly the Rongelap group), most of which were superficial. There were several days' difference in the latent period for lesions on different skin areas. The order of appearance was roughly as follows: scalp (with epilation), neck, axillary region, antecubital fossae, feet, arms, legs, and trunk. Lesions on the flexor surfaces thus tended to precede those on the extensor surfaces. Tables 1 and 2 show the incidence according to age and time of appearance of lesions in the various groups.

In the early stages all lesions were characterized by hyperpigmentation in the form of macules, papules, or raised plaques. These frequently were small, 1-2 mm. areas at first, but tended to coalesce into larger lesions in a few days. Most of them had a dry, thickened, leathery feel.

In those lesions which were superficial in nature the pigmented stage was followed after several days by dry, scaly desquamation from the central part of the lesion outward, leaving pink to white somewhat thinned epithelium. As the desquamation proceeded outward, a characteristic appearance of a central depigmented area fringed with an irregular hyperpigmented zone was seen (plate 11). Repigmentation began in the central area and spread outward over the next few weeks leaving skin of relatively normal appearance. Plates 3, 4, 11, and 12 show superficial lesions as they appeared initially and six months later. One of the mildest manifestations of skin injury was the development of a blotchy increased pigmentation of the skin with barely perceptible desquamation. Such lesions were most often noted on the face and trunk.

\* The description of lesions refers to the Marshallese unless otherwise indicated.

Table 1. - Lesions in Rongelap Group

Type of Lesion	Percent of Total in Age Group having Indicated Lesion				Median Time of First Observation of Lesions*
	Age 0 - 5 yrs. (13 people)	Age 6 - 15 yrs. (13 people)	Age 16 yrs. and Over (38 people)	Total Group (64 people)	
Epilation					
1 plus	7.6	38.4	13.8	17.2	17
2 plus	38.6	30.7	5.5	17.2	17
3 plus	53.8	23.0	8.3	22.0	16
Total	100.0	92.1	27.6	56.2	16
Skin Lesions					
anus-groin	38.4	0.0	0.0	7.8	17
scalp	100.0	100.0	37.0	62.5	18
neck	69.2	76.9	68.0	70.3	21
axilla	61.5	7.6	15.7	23.4	21
antecubital fossae	30.7	38.4	34.2	34.4	28
hands-wrists	30.7	23.0	18.4	21.8	33
feet	23.0	53.8	53.0	45.3	28
arms	15.3	15.3	10.3	12.5	31
legs	7.6	23.0	4.3	7.8	33
trunk	15.3	23.0	4.3	9.4	33
Nail Pigmentation	61.5	100.0	95.0	89.0	38

\* Post-exposure Days

Table 2. - Lesions in Ailingnae and Rongerik Groups

Type of Lesion	Ailingnae Group (18 people)		Rongerik Group (28 people)	
	Percent of Total with Lesions	Mean Time of Appearance*	Percent of Total with Lesions	Mean Time of Appearance*
Epilation	16.7	27	3.5**	42
Lesions of:				
scalp and face	38.9	26	10.7	32
neck and shoulders	61.0	27	14.3	30
back	0.0		7.1	28
axilla	22.2	24	3.5	23
antecubital fossae	11.1	28	25.0	29
hand and wrist	5.6	38	3.5	47
feet	16.7	33	3.5	43
legs	5.6	44	0.0	
Nail Discoloration	77.7	38	17.9 (All negroes)	40

\* Days post-exposure

\*\* One case claimed slight epilation

Scalp lesions usually accompanied epilation (plates 13,17, and 19). Some individuals tended to develop new scalp lesions over a period of about a month. Neck lesions were usually of "necklace" distribution, beginning at the front usually and spreading posteriorly. They were more severe in women where the thick hair touched the nape of the neck. Neck lesions are illustrated in plates 1-4. Axillary lesions (plate 11) usually consisted of coalescing papules. Antecubital fossae lesions usually were characterized by thickened plaque formation. Several babies and one woman developed lesions in the anal region which though not deep were painful due to excoriation of the epidermis. They healed rapidly.

Lesions of a deeper nature were seen on the scalp, neck, feet, and in one case on the ear. The early pigmented lesions were similar to those described above but tended to be larger. They were characterized by transepidermal necrosis with wet desquamation leaving weeping, crusting ulcerations. Vesiculation was not observed except with foot lesions which developed bullae, frequently several centimeters in diameter, beneath thickened pigmented plaques. After several days the bullae ruptured and desquamated leaving raw ulcers. Some of these lesions, particularly of the feet, became secondarily infected requiring specific antibiotic therapy. However, most healed rapidly and new epithelium covered the ulcerated areas in a week or ten days. Foot lesions are illustrated in plates 5-10. One ear lesion (plates 13-16) took several months to heal.

The repigmentation process in some of these deeper lesions presented certain abnormalities. Neck lesions tended to develop a dusky, grayish-brown pigmentation associated with a thickened "orange peel" appearance. Histological appearance of epidermal rugosity was also noted in these lesions (see section on histopathology). In addition, the deeper lesions of the feet failed to repigment, remaining a pink to white color.

At examination 6 months and 1 year after the exposure, the skin appeared normal with no residual changes in the vast majority of cases. However, some of the deeper lesions continued to show slight evidence of residual damage. Foremost among these was the ear lesion which showed healing but with considerable scarring, atrophy, scaling of the epidermis, and gross telangiectasis. This was the only lesion in which future breakdown appeared likely. By 6 months the hyperpigmentation and thickening of the skin of the neck lesions had greatly subsided and by 1 year little of this residual change could be seen. Foot lesions continued to show no repigmentation at sites of deepest involvement and some atrophy of the skin in these areas was apparent.

#### *b. Microscopic*

Biopsies were taken of seven neck, and one axillary lesion in the Rongelap group during the third to fourth week after exposure. At the time of biopsy these lesions were in the hyperpigmented stage with little or no desquamation. Most of the biopsies were taken from individuals with lesions of greater than average severity. A second series of biopsies (repeats in three individuals) were taken from this group, four at the seventh week and five at the eighth week post-exposure. These were taken from the neck and antecubital fossae. All of these lesions had desquamated and the depigmented skin had repigmented to a dusky, gray color with some thickening of the skin ("orange-peel" appearance), plates 25 and 27. Biopsies were not taken from open lesions or from the feet for fear of infection. A third series of 11 biopsies were taken from the Rongelap group at 6 months along with several control biopsies from unexposed natives. Material was obtained from sites of previous lesions, mostly in individuals who had previous biopsies.

All biopsy wounds healed rapidly within a week to 10 days with no secondary complications.

The microscopic findings are summarized as follows:

*First series - 3rd to 4th week. Epidermis.* - Transepidermal damage was noted with a few intervening arcades showing less damage (plates 21 and 22). The epidermis in the most ex-



tensively involved areas showed considerable atrophy with flattening of the rete pegs and in places the epidermis was reduced to a thickness of two to three cells (plates 21, 23, and 24). The cells of the malpighian layer showed pleomorphic nuclei, pyknosis and cytoplasmic halos, giant cells and in a few instances multinucleated cells. Pyknosis of cells of the basal layer was commonly seen. Focal disorganization of the malpighian and basal layers was usually present in the more extensively damaged arcades (plate 23). Cells laden with pigment were frequently present throughout the epidermis and intercellular pigment was noted in some sections. The stratum granulosum was usually atrophic or even absent. Imperfect keratinization with parakeratosis was visible in all sections. The stratum corneum was loosely fibrillated and hyperkeratotic. Sporadic cases showed early dyskeratosis.

The arcades of minimal damage were usually found in areas where sweat ducts approached the epidermis (plate 22). There was an apparent increase in the number of cells and mitotic figures along the neck of the ducts and the adjoining areas where regeneration was underway. In these areas the stratum granulosum appeared almost normal in width. In contrast to the more severely damaged areas where pigment was increased, these areas of minimal damage showed an actual decrease, being almost entirely pigment free.

*Dermis.* - Changes in the dermis were confined largely to the pars papillaris and superficial pars reticularis (plates 21-24). Mild edema in some cases was noted. Capillary loops were often indistinct and when discernible they frequently were associated with an increased number of pericytes. The endothelial cells showed swelling and were polygonal in shape. Telangiectatic changes were noted in these areas where the overlying epidermis showed greatest damage which were associated with perivascular lymphocytic infiltration. Chromatophores, filled with melanin pigment, were prominent in the superficial dermis. The fine elastic fibrils running into the pars papillaris were often altered or absent.

Little if any damage was seen below the superficial pars reticularis. The hair follicles were narrow and in most instances devoid of shafts in this region. There was some telangiectasis of the capillaries and slight mononuclear cell infiltration. Some of the large elastic fibers in this region showed slight swelling in some cases. No damage to fibrocytes or collagen fibers was noted.

*Second series - 7th and 8th weeks post-exposure. Epidermis.* - In general, reparative processes of the epidermis appeared to have been good, except for a few persistent areas of atrophy with narrowing of the epidermis and finger-like downgrowths of the stratum malpighii (plate 27). These changes occurred in areas of greatest narrowing of the stratum granulosum. In such areas basal cells often showed accentuated pigment content. There were many outward epidermal excrescences covered by thickened stratum corneum, still loosely laminated, (plate 25), which probably accounted for the "orange-peel" appearance of the skin noted grossly. In almost all instances the basal layer was intact with little or no disorganization. There were a few scattered areas in which occasional epithelial cells with pyknotic nuclei and perinuclear cytoplasmic halos occurred in the malpighian layers (plate 26). There were occasional arcades in which the epidermis and particularly the stratum granulosum, appeared to be widened. These occurred primarily in relation to contiguous sweat gland ducts where the latter penetrated the epidermis. A narrow zone of parakeratosis and amorphous debris was still present between the stratum granulosum and the loosely laminated stratum corneum. The stratum lucidum was not apparent.

*Dermis.* - The capillary loops in the dermal papillae were not uniformly distinct. Pericytes remained in increased number but fewer lymphocytes were present. Generally, there was a slight telangiectasis of the capillaries in the pars papillaris and the superficial pars reticularis (plate 27). There was some edema of the pars papillaris (plate 25). Scattered pigment-laden chromatophores were irregularly distributed in the papillary layer (plate 26).

In some cases hair shafts in the superficial pars reticularis were narrow or absent; in others the hair shafts appeared normal. Small hair follicles (plate 25) and sweat ducts in some cases showed mild atrophy.

Biopsies of three pigmented lesions were taken from two of the white Americans of the Rongerik group. Only one of the three gave evidence of damage, which was slight and confined to the epidermis.

*Third series - 6th month post-exposure.* - Sections of skin at this time revealed some changes persisting in the epidermis and to a lesser extent in the dermis (plates 28 and 29).

*Epidermis.* - The following changes were found to varying degrees: focal atrophy of the stratum granulosum; slight focal pigmentary disturbances in cells of the basal layer; slight to moderate hyperkeratinization; and slight disturbances in polarity of epithelial cells in the still persistent basal papillary projections.

*Dermis.* - In the dermis, telangiectasis superficially persisted from a slight to moderate degree in most of the sections, and contributed the only abnormality noted.

## 2. Epilation

The incidence and time of appearance of epilation in the various groups is illustrated in tables 1 and 2, and figure 1. Epilation was first observed on the fourteenth post-exposure day in the Rongelap group, and somewhat later in the other groups. It was of a spotty nature and was confined almost entirely to the head region. Epilation was divided arbitrarily into three degrees of severity. "1+" indicated loss of hair without obvious thinning; "2+" indicated loss of hair sufficient to cause thin spots; and "3+" indicated an extensive epilation with bald spots. Table 1 illustrates that there was a greater degree of epilation in the children (0 to 15 years), with over 90 percent developing epilation to some degree as compared with only 28 percent in the older age group. The preponderance of scalp lesions in the areas of epilation indicated that radiation from the fallout material on the skin was primarily responsible for the epilation. Only three cases of mild epilation developed in Ailingnae children and one case of questionable epilation in one of the Americans.

Regrowth of hair in almost all individuals was noted commencing some time during the third month post-exposure. By the 6 months' examination complete regrowth of hair normal in color, texture, and abundance had taken place. Plates 13-15, 17, 18, and 19 show epilation and regrowth of hair.

## 3. Nail Pigmentation.

An unexpected observation was the appearance of a bluish-brown pigmentation of the fingernails which was first well documented on the 23rd post-exposure day. The discoloration began in the semilunar area of the fingernails (to a lesser extent in the toenails), and tended to spread outward sometimes in streaks. As the discolored area grew outwards the semilunar area usually became clear. Plate 20 shows pigmented bands in the nails at 77 days. At six months the pigmentation had grown out with the nails, and was no longer evident except in three cases which still showed pigment at the distal end of the nail. The pigment appeared to be on the under side of the nail plate, between it and the nail bed. Discoloration of the nails was seen in a large proportion of the two higher exposure groups (tables 1 and 2). The phenomenon appeared to be a radiation response peculiar to the dark-skinned races since it was seen in all of the exposed American Negroes and in none of the white Americans. This lesion was not observed in the Utirik people or in unexposed Marshallese. Since the nail pigmentation occurred in individuals without skin lesions, it appeared to be the result of a more penetrating gamma component of radiation.

## TREATMENT

The treatment of the skin lesions was largely nonspecific. Most of the superficial lesions were treated with calamine lotion with one percent phenol, which in most cases relieved the itching and burning. A few of the hyperpigmented lesions not relieved by calamine with phenol were treated with pontocaine ointment, with apparent success. When the epithelium was desquamating, all lesions were treated by daily washing with soap and water followed by the application of a water soluble vanishing type ointment which kept the injured skin soft and pliable. Raw areas, which became secondarily infected, were cleansed with soap and aureomycin ointment dressings were applied. Bullous lesions of the feet were left intact as long as no symptoms were present. If painful, the bullous fluid was aspirated with sterile technique to remove the clear straw-colored fluid and a pressure dressing applied. A single aspiration was adequate since the bullae did not refill. In one instance, an extensive, raw, weeping ulcer developed for which penicillin was given for two days. During this time the lesion developed healthy granulation tissue. Some of the lesions of the skin of the foot remained thickened and less pliable after desquamation. This was relieved by the use of vaseline or cocoa butter to soften the tissues. One persistent ear lesion did not heal after desquamation. This was treated daily with warm boric acid compresses and washing with surgical soap to remove the eschar. Slowly, regenerating epithelium grew in from the edges of the ulcer. Upon re-examination 6 months after exposure, healing was complete with a depigmented scar remaining as evidence of the previous ulceration.

## FACTORS INFLUENCING SEVERITY OF THE LESIONS

### 1. *Character of the Fallout Material.*

This material was composed mainly of calcium oxide from coral, with adherent fission products. Fifty to eighty percent of the beta rays emanating from this material during the exposure period were soft with an average energy of about 100 kev. Since 80 microns of tissue produces 50 percent attenuation of such radiation (1), a greater portion of energy was dissipated in the epidermis which is roughly forty to seventy microns in thickness. The remaining 20 to 50 percent of the beta rays had an average energy of approximately 600 kev. The latter would penetrate well into the derma since it takes 800 microns of tissue to produce 50 percent attenuation of this energy radiation (1,2). In addition, a wide spectrum of gamma energies irradiated the skin. Approximately 10 percent of the total gamma spectrum was below 80 kev which would be absorbed largely in the superficial layers of the skin. The remainder of the gamma spectrum was distributed between 100 and 1,600 kev with a large proportion between 600 and 800 kev.

### 2. *Dose to the skin.*

The skin lesions observed resulted primarily from beta radiation from fallout material deposited on the skin, with minimal or no contribution from chemical irritation. The gamma dose to the skin was small compared with the beta dose, and thus relatively unimportant in producing the lesions. The entire surface of the body of the people of Rongelap received approximately 175 r from gamma irradiation derived from fission products distributed on the ground, trees, and buildings. To this 175 r would have to be added the beta component from this source which might be large in view of the high beta to gamma ratio in fission products. To these doses would have to be added the major contribution (beta) from the material in contact with the skin. The latter cannot be calculated, or estimated biologically with any degree of accuracy. A rough approximation of the dose received at the hair follicles can be made as follows: since epilation occurred, the hair follicles must have received a dose in excess of the known minimal epilating dose of about 400 r for 200 kvp X-rays. Since regrowth of hair occurred, the upper limit of dose at the depth of the hair follicle must not have exceeded the permanent epilating dose of around 700 r of 200 kvp X-ray (3). From this a rough idea of surface dose may be made. A dose to the hair follicles comparable to 400-700 r of X-radiation must have been

due almost entirely to the more penetrating beta component (average energy, 600 kev). Therefore, the surface dose in rep from this component alone must have been of the order 4 to 5 times this depth dose, i.e., roughly 2,000-5,000 rep. The soft component (average energy, 100 kev) must have contributed a considerably larger share to the surface dose though with only superficial penetration.

### 3. *Protective Factors.*

The following factors were found to afford some degree of protection:

a. *Shelter.* - Those individuals who remained indoors or under the trees during the fallout period showed some degree of protection as compared with those who were in the open during that period.

b. *Bathing.* - Those who bathed during or shortly after the fallout were protected to varying degrees. Small children who went wading in the ocean developed fewer foot lesions. Most of the Americans who were more aware of the danger of the fallout, took shelter in their butler-type buildings, bathed and changed clothes and consequently developed only very mild beta lesions.

c. *Clothing.* - Clothing, even a single layer of cotton material offered almost complete protection, as was demonstrated by the fact that lesions developed almost entirely on the exposed parts of the body.

### 4. *Factors favoring the development of lesions.*

a. *Areas of more profuse perspiration.* - Lesions were more numerous in areas where perspiration is abundant such as the folds of the neck, axillae, and antecubital fossae.

b. *Delay in decontamination.* - There was a delay of one to two days before satisfactory decontamination was possible. The prolonged contact of radioactive materials on the skin during this period increased the dose to the skin. However, the dose rate fell off rapidly and decontamination would have to have been prompt in order to have been very effective.

## CORRELATION WITH HEMATOLOGICAL FINDINGS

Attempts were made at correlation of the severity and extensiveness of skin lesions with maximum depression of platelet, lymphocyte, and neutrophile counts for individuals in the Rongelap group. No positive correlation was found. Thus, the contamination of the skin apparently did not significantly contribute to the total-body dose of irradiation. It is possible that the skin lesions may have been partly responsible for the fluctuation in leukocyte counts during the period when the lesions were most acute.

## DISCUSSION

There has been little previous experience with radiation dermatitis resulting from exposure to fallout material from nuclear detonations, and the general consensus until this event has been that the hazard from fallout material was negligible. From the present experience it is evident that following detonation of a large scale device close to the ground, serious exposure of personnel with resulting radiation lesions of the skin may occur from fallout material, even at considerable distances from the site of detonation. This incident is the first example of large numbers of radiation burns of human beings produced by exposure to fallout material. With the Hiroshima and Nagasaki detonations fallout was not a problem since the bombs were detonated high in the air. The flash burns of the Japanese were due to thermal radiation only.

Following the Alamogordo atomic detonation there were a number of cattle that developed lesions on their backs due to the deposit of fallout material (4). Also, following a deton-

ation at the Nevada Proving Grounds, 16 horses developed lesions resulting from fallout deposit on their backs (5).

Knowlton *et al.* (6) described burns of the hands of four individuals who were handling fission product material following detonation of a nuclear device. These burns were due largely to beta radiation. The gross lesions of the hands occurred from an exposure of about one hour, resulting in doses between 3,000 and 16,000 rep of beta radiation (maximum energy about 1 Mev) with a small gamma component considered to be insignificant. The lesions were described as developing in four phases: (1) An initial phase which began almost immediately after exposure and consisted of an erythema with tingling and burning of the hands, reaching a peak in 48 hours and subsiding rapidly so that by 3 to 5 days there was a relative absence of signs and symptoms; (2) A second phase which occurred from about the third to the sixth or eighth day, and was characterized by a more severe erythema; (3) The third phase at 8 to 12 days, which was characterized by vesicle and bullae formation. The erythema spread to new areas during the following two weeks, and the active process subsided by 24 to 32 days. The bullae dried up, and desquamation and epithelization took place in less severely damaged areas; and (4) The fourth phase or chronic stage was characterized by further breakdown of skin with necrosis in areas which were damaged sufficiently to compromise the blood supply. Atrophy of the epidermis and loss of epithelial structures took place, which necessitated skin grafting in some cases.

Robbins *et al.* (7) reported six cases accidentally exposed over much of their bodies to scattered cathode rays (beta) from a 1,200 kv primary beam with exposure time of about 2 minutes and a rough estimation of dose to the skin of between 1,000 and 2,000 rep. The lesions described were similar to those reported by Knowlton *et al.* with a primary erythema developing within 36 hours; secondary erythema with vesiculation and bullae formation appearing about 12 to 14 days later; and, in the more severely affected, a tertiary phase characterized by further breakdown of the skin. In comparison with severe roentgen ray reactions these investigators stressed the unique periodicity of cathode ray burns, relative absence of deep damage to the skin, less pain, greater rapidity of healing, and absence of pigmentation. These points would apply to the Marshallese lesions except for the multiphasic reactions and absence of pigmentation. Crawford (8) reports a case of cathode ray burns of the hands which were similar to those described by Robbins *et al.*

Experimental beta radiation burns in human beings have been reported by Low-Beer (9) and Wirth and Raper (10). Both investigators used  $P^{32}$  discs applied to the flexor surfaces of the arms, forearms, or thighs for varying lengths of time. Low-Beer reported "monophasic" skin reactions. He found that a calculated dose of 143 rep to the first millimeter of skin, ignoring self-absorption, produced a threshold erythema. Dry, scaly desquamation was produced by 7,200 rep in the first millimeter and bullous, wet desquamation was produced by 17,000 rep to the first millimeter. Erythema developed in three to four days, followed later by pigmentation and desquamation with higher doses. Recovery was observed with doses of 17,000 rep. The lesions later showed depigmented centers with hyperpigmented edges (also seen in the present cases).

Wirth and Raper (10) produced primary erythema within six hours after exposure to a dose of 635 to 1,180 rep of  $P^{32}$  radiation. Minute vesicles with dry, spotty desquamation were noted with 1,180 rep at about the fifth to sixth weeks post-exposure.

There were 23 Japanese fishermen exposed to the same fallout accident which involved the Marshallese and Americans. There were many similarities in appearance of skin lesions that developed. Pigmentation was also common in the Japanese and some degree of erythema was reported accompanying some of their lesions (11) which was not seen in the Marshallese. Distribution of lesions was not the same due to different parts of the body being protected by clothing. For example, in the Japanese scalp lesions and epilation were more common on the crown of the head since handkerchiefs were usually worn around the head leaving the crown exposed. Wearing

of shoes protected against foot lesions in the Japanese, but lesions of the hands between thumb and index finger were common apparently due to handling contaminated fishing lines. Difficult to explain were the increased number of lesions of belt line distribution in the fishermen as compared with the Marshallese. In this connection there were several American sailors on naval vessels who also developed mild pigmented lesions of belt-line distribution from fallout on the ships. From available information, the severity and course of the lesions in the Japanese fishermen appeared to be similar to those seen in the Rongelap Marshallese group.

The lesions reported in this paper did not follow precisely the same course as those beta radiation lesions described by Knowlton, Robbins, and others and they presented certain unique features which merit further discussion.

The early symptoms of itching and burning of the skin and eyes were probably due mainly to skin irradiation from the fallout material. However, the chemical nature of this material may have contributed to the irritation. It has been noted (12) that irritating chemicals applied during or shortly after irradiation enhance the effects of radiation.

The lack of prominence of an erythema was notable, particularly in view of the severity of some of the lesions that developed. Wilhelmy (13) states that erythema only occurs when the dose reaching the papillary layer exceeds a certain level. Perhaps due to the low energy of the beta radiation the dose to the dermis was insufficient to evoke the response. On the other hand, the darkness of the skin and the development of hyperpigmentation may have masked an erythema. Microscopically, a superficial hyperemia was not a notable finding.

Wirth and Raper (10) point out that they were impressed in their studies on  $P^{32}$  radiation of the human skin with the difficulty of distinguishing between true erythema and tanning, particularly in the skin of brunette individuals. It was unfortunate that color filters were not available to aid in distinguishing an erythema as suggested by Harris et al. (14).

In general, the length of the latent period before development of lesions of the skin is considered to be roughly inversely proportional to the dose of radiation (15, 16). In the present series of cases the relatively long latent period is suggestive of a low dose of radiation. Due to the wide spectrum of beta energies and particulate distribution of radioactive material, strict comparisons cannot be made with previous experience. However, the later development of less severe lesions in the Ailingnae and Rongerik groups as contrasted with earlier development of more serious lesions in the Rongelap group is in keeping with a lower skin dose in the former, and a higher skin dose in the latter. It is of interest, however, that the latent period was dependent to some extent on anatomical location. The foot lesions which were generally the most severe lesions encountered had a longer latent period than did the less severe lesions occurring elsewhere on the body. It seems likely that the greater severity of these lesions was due to a greater radiation dose to the feet since the feet received an appreciably greater contribution from close proximity to the contaminated ground. Perhaps such differences in latent period may be related to thickness of the epidermis, differences in length of mitotic cycles or other inherent characteristics of skin in different areas of the body.

The histopathological changes noted, such as destructive and atrophic changes of the epidermis, disturbances in keratinization, and atrophy of hair follicles when taken together are consistent with radiation injury to the skin (9, 12, 17, 18, 19, and 20). Severe injury to the dermis and blood vessels was not observed. The minimal dermal injury with severe epidermal injury is in keeping with the large component of low energy beta material present, resulting in absorption of the greater portion of the energy in the epidermis.

Hyperpigmentation of injured areas was a consistent finding in the Marshallese and the American Negroes. Pigmented lesions were also observed to a lesser extent in the white Americans. Such pronounced pigmentation is not characteristic of the usual lesions as described following exposure to beta or penetrating radiation, but may be more typical of the response to ultra soft roentgen or "Grenz rays" (21).

There is no satisfactory explanation for the darker dusky-gray color that appeared in some of the skin lesions as healing progressed. The color changes may have been due to alterations in local pigment production, vascular changes, or a thinning of the epidermis, rendering it more translucent with resultant darker appearance of the pigment layer. The return to near normal in this pigmentation by 6 months showed the transient nature of this change. The continued absence of pigmentation at the site of the deeper foot lesions at six months and one year later suggests that the pigment-producing elements in these areas may have been permanently damaged.

The unique features of the lesions such as the marked pigmentation changes, the absence of obvious multiphasic response, the long latent period, and the severe, spotty epidermal injury with minimal dermal injury, may have been partly related to biological factors and partly to physical radiation factors.

*Among the physical parameters* the particulate nature and uneven distribution of the fallout material was no doubt responsible for the spotty nature of the lesions. Severity of lesions were due to factors related to the skin dose, determined by the time after detonation that contamination occurred, and the length of time before decontamination was accomplished, and radiochemical composition of the fallout material particularly in regard to the beta energy spectrum which determined the skin depth dose.

*Biological factors* such as varying degrees of skin pigmentation are known to affect the radiation response. It is generally recognized that blond individuals are more sensitive than brunettes (17). Many of the characteristics noted in these lesions, particularly the marked pigmentation changes, may have been related to the fact that the exposed population was largely a dark-skinned race.\* The part of the body involved was important. As was pointed out the flexor surfaces with thinner epithelium are considered to be more sensitive than the extensor surfaces with thicker epithelium. Other inherent differences in sensitivity of different areas may exist.

In table 3 are listed the approximate surface skin doses required to produce recognizable epidermal injury from beta radiation in animals. It is apparent from the table that beta ray energy is of considerable importance in determining the degree of injury. According to Moritz and Henriques, the difference in dose between that required to produce threshold skin damage and that for permanent damage in pigs is 500 to 1,000 rep (26). One is not justified in comparing animal lesions from known doses with lesions in the exposed individuals in this study in order to estimate the skin dose, since species differences in response may exist, and certain radiation factors are not well established, such as accurate knowledge of the beta spectrum of the fallout material and dose rate. Comparison with human data suffers from the drawback of wide differences of radiation doses reported to produce stated effects.

*The fact that there was so little secondary infection of these lesions* may be partly attributed to the daily cleansing and care given them. However, the low incidence of infection, even during the acute stages, also indicate that the humoral and cellular defenses were not sufficiently altered under the circumstances to predispose to infections. This conclusion is emphasized by the fact that an epidemic of upper respiratory infections, as well as other diseases encountered, occurred concomitantly with the skin lesions without untoward results even though significant leukopenia was evident. It is conceivable, however, that with a slightly larger dose of whole-body radiation, the defenses against infection might have been sufficiently impaired to have resulted in serious complications from skin lesions of the severity encountered.

\* Reported clinical experience with radiation skin lesions is based predominantly on the response of white-skinned people, whereas the lesions described herein were observed primarily in Marshallese (Micronesian) people.

Table 3. - Surface Doses Required To Produce Recognizable Epidermal Injury

Investigator	Animal	Isotope	Average Energy (Mev)	Surface Dose (rep)
Henshaw, et al. (22)	rats	P <sup>32</sup>	0.5	1,500-4,000
Raper and Barnes (23)	rats	P <sup>32</sup>	0.5	4,000
Raper and Barnes (23)	mice	P <sup>32</sup>	0.5	2,500
Snider and Raper (24)	mice	P <sup>32</sup>	0.5	2,500
Raper and Barnes (23)	rabbits	P <sup>32</sup>	0.5	5,000
Lushbaugh (25)	sheep	Sr <sup>90</sup>	0.3	2,500-5,000
Moritz and Henriques (26)	pigs	S <sup>35</sup>	0.05	20,000-30,000
" "	pigs	Co <sup>60</sup>	0.01	4,000-5,000
" "	pigs	Cs <sup>137</sup>	0.2	2,000-3,000
" "	pigs	Sr <sup>90</sup>	0.3	1,500-2,000
" "	pigs	Y <sup>91</sup>	0.5	1,500-2,000
" "	pigs	Y <sup>90</sup>	0.7	1,500-2,000

The outlook for the development of malignancies at the site of healed lesions is uncertain. Certain factors tend to make the outlook more favorable. (a) The majority of the lesions were superficial. (b) Visible signs of chronic radiation dermatitis were absent in the vast majority of cases. Such changes have been generally observed prior to the development of radiation cancer. (c) The lack of any marked histological damage six months after exposure. (d) The fact that low energy radiation was chiefly responsible for the skin lesions. It has been reported (27) that none of 1,100 individuals exposed to low voltage X-ray for dermatological conditions developed epidermoid carcinoma five to twenty-three years after treatment. (e) The fact that epitheliomata rarely develop after a single dose of radiation to the skin (12). (f) The incidence of skin cancer in Negroes is one-sixth to one-ninth the incidence in Caucasians (28) in the United States.

Other factors tend to make the outlook less favorable. (a) Deeper lesions of the feet and neck continued to show pigment aberrations and slight atrophy at 1 year, and one severe ear lesion showed marked atrophy and scarring at this time. (b) It is not known whether or not radiation of the epidermis *per se* can predispose to malignant change. Since the epidermis was heavily irradiated in these cases, compared with the dermis, this becomes an important consideration. (c) Since many children and young adults were involved, the life expectancy of a large number of the individuals will exceed the long induction period for the development of radiation cancer observed in radiologists. (d) Exposure to tropical sunlight, potentially carcinogenic in itself, may increase the probability of neoplastic change. (e) The influence of the sublethal whole-body exposure received by these people on skin cancer induction is not known.

The occurrence of epilation 2 to 3 weeks after exposure corresponds roughly to the time of appearance of epilation in the Japanese exposed to gamma radiation at Hiroshima and Nagasaki (29, 30). Since the greater amount of epilation occurred over a period of a week to ten days there was apparently no phasic response dependent on the growth cycle of the follicles (inactive, or telogen and active, or anagen follicles) as has been reported (31, 32).

The regrowth of hair, beginning about 9 weeks after exposure in the Marshallese, was about the same time as noted in the Japanese fisherman (11), and slightly later than the time of regrowth (6 to 8 weeks) noted in the Japanese bomb casualties. In contrast to the marked pigmentation changes noted in the irradiated skin of the Marshallese, there were no pigment aberrations in the new hair which was observed to be of normal texture and abundance at six months. Increased graying has been reported in animals (33-36) but has not been seen in human beings. Neither was there any appearance of dark hair in aged individuals who already had



gray hair as has been reported in human beings (32, 37, and 38). In the Japanese bomb casualties (30) and the Japanese fishermen (11) the regrown hair was also normal in color, texture, and abundance.

The nature of the bluish-brown transverse bands of pigmentation that developed beneath the nails is not known. Since it occurred in the majority of the more heavily exposed Marshallese groups and in all five of the American Negroes, but none of the white Americans, it appeared to be a response peculiar to dark-skinned races. The phenomenon was apparently produced by whole-body radiation with dosage as low as 75 r since this was the estimated dose the American Negroes received in the absence of significant contamination of the hands. Sutton (39) has reported a case of similar fingernail pigmentation which developed in a negress, following 150 r of soft X-irradiation to the hands.

Certain conclusions may be drawn from this experience concerning the hazard of radioactive fallout in regard to the skin. (1) Serious contamination of personnel with fallout may occur many miles from the site of detonation of a nuclear device; (2) Beta radiation of the skin may result in extensive epilation and skin lesions even though the dose of whole-body penetrating radiation received may be sublethal; (3) Just as the dose of whole-body radiation can be decreased by early evacuation so can skin irradiation be reduced by prompt personnel decontamination. One can conceive of a situation following fallout where early evacuation from a field of radiation might result in a minimal whole-body dose of radiation, but due to delayed decontamination of the skin for various reasons, serious skin exposure might occur. The reverse situation might occur if decontamination were possible early, but evacuations were delayed and adequate shelter against penetrating radiation were not available; (4) The importance of prompt decontamination cannot be overemphasized. The earlier the fallout occurs the more radioactive is the material and the higher the dose rate. Therefore, prompt decontamination is exceedingly important when fallout occurs within several hours after the detonation. Difficulty encountered in decontamination of the hair may necessitate cutting off the hair or shaving the head if contamination is great; (5) Warm weather would tend to aggravate the hazard since increased perspiration would tend to concentrate the material and cause it to stick, and less clothing would increase exposure and; (6) Simple preventive measures may completely eliminate or greatly reduce the hazard of skin irradiation. Recognition of the powdery, ash-like material as radioactive fallout should not be difficult. Preventive measures center around avoidance of the deposit of fallout on the skin. Taking shelter or keeping indoors during the fallout are obvious safety measures and covering as much of the body as possible with clothing, even a single layer, will provide marked protection.

#### SUMMARY

Radioactive fallout from an experimental thermonuclear detonation resulted in accidental exposure of 239 Marshallese people, and 28 American servicemen. Whole-body exposure to penetrating radiation, beta radiation of the skin, and a small amount of internal absorption of radioactive materials occurred. Beta lesions of the skin, epilation and nail pigmentation are described. This report covers the results of examinations immediately after the accident, again at 6 months and at 1 year after the accident. During the first 24 to 48 hours, itching and burning sensations of the skin occurred lasting only a day or two. Lesions began developing 2 and 3 weeks later on exposed parts of the body in roughly the following order: scalp with epilation, neck, axillae, antecubital fossae, feet, limbs and trunk. No primary or secondary erythema was observed. The majority of lesions were superficial and occurred in about 90 percent of the higher exposure groups. They were characterized by pigmentation which was accompanied by mild itching and burning sensations of the skin, followed by dry desquamation leaving depigmented areas which gradually repigmented to normal color. Some 20 percent of the lesions in the highest exposure group were deeper and were characterized by pain, wet desquamation and ulceration. Some of these deeper lesions showed persisting aberrations in pigmentation and some degree of atrophy. There has been no breakdown of the skin noted in any lesions after

healing. Histologic study of biopsies of lesions showed changes consistent with radiation injury. These changes were much more pronounced in the epidermis than in the dermis. A few histologic changes were still in evidence at the site of deeper lesions six months after the accident. With only a few exceptions the lesions did not become secondarily infected nor were they associated with systemic effects. They healed rapidly, usually with nonspecific treatment. Epilation was spotty and occurred mainly in the children. Regrowth of normal hair occurred beginning about the third month and was complete by the sixth month. Discoloration of the nails in the semilunar area occurred in the majority of people in the higher exposure groups. It was first noticed about the third week after exposure and had completely grown out with the nails in most cases by six months.

#### ACKNOWLEDGMENT

The authors wish to express their sincere appreciation to Dr. E. P. Cronkite of Brookhaven National Laboratory, who was in charge of this mission, and other members of the team for their invaluable cooperation and assistance. We are also deeply grateful to Billiet Edmond, Marshallese school teacher of the Rongelap people, for his great help in interpreting, and also to Miss Pat Roan of NRDL for histological preparation of tissues; to William Murray and George Needham of NRDL and C. P. A. Strome, HMC, USN of NMRI for assistance in photography; to C. R. Sipe, HMC, USN of NMRI for assistance in preparation of this report; and to Cdr. R. B. Williams, MC, USN of NMRI for helpful suggestions in editing the manuscript.

# BIBLIOGRAPHY

1. Henriques, F. W., Jr. Effect of beta rays on the skin as a function of the energy, intensity, and duration of radiation. *J. Lab. Investigation* 1: 153, 1952.
2. Glendenin, L. E. Determination of the energy of beta-particles and photons by absorption. *Nucleonics* 2 (1): 12-32, 1948.
3. Warren, Shields. Effects of radiation on normal tissues. *Arch. Path.* 35: 304-353, 1943.
4. Paysinger, J., Plumlee, M. P., Sikes, D., West, J. L., Comar, C. L., Hansard, S. L., Hobbs, C. S., and Hood, S. L. Fission product retention and pathology of Alamogordo cattle. AEC Report UT-AEC-1, 1953.
5. Major Activities in Atomic Energy Programs, July-December 1953. United States Atomic Energy Commission, 15th Semi-annual Report, January 1954, p. 50.
6. Knowlton, N. P., Leifer, E., Hogness, J. R., Hempelmann, Louis H., Blaney, Loren F., Gill, Dan C., Oakes, William R., and Shafer, Charles L. Beta ray burns of human skin. *J.A.M.A.* 141: 239-246, 1949.
7. Robbins, Laurence L., Aub, Joseph C., Cope, Oliver, Cogan, David G., Langohr, John L., Cloud, R. W., and Merrill, Oliver E. Superficial "burns" of skin and eyes from scattered cathode rays. *Radiology* 46: 1-23, 1946.
8. Crawford, Stanley. Leonard or cathode "ray" dermatitis. *Arch. of Dermat. and Syph.* 27: 579-583, 1933.
9. Low-Beer, B.V.A. External therapeutic use of radioactive phosphorous, 1. Erythema studies. *Radiology* 47: 213, 1946.
10. Wirth, J. E., and Raper, J. R. Biological Effects of External Beta Radiation. Chapter 12, McGraw-Hill Book Co., Inc., First Edition, New York, 1951.
11. Koyama, Y., et al. Iryo (published by Iryo Dokokai, Medical Affairs Bureau, Ministry of Health and Welfare, Tokyo, Japan). 9: No. 1, 5-45, Jan. 1955.
12. MacKee, G. M., Cipollaro, A. C., and Montgomery, H. M. X-ray and Radium Treatment of Diseases of the Skin. Fourth edition, Lea and Febiger, Philadelphia, 1947.
13. Wilhelmy, Ernst. Ueber die Reaktion der Haut auf Langwellige Roentgenstrahlen und Kathodenstrahlen. *Strahlentherapie* 55: 498-523, 1936.
14. Harris, M., Leddy, E. T., and Sheard, C. Spectrophotometric analysis of color of skin following irradiation by roentgen rays. *Radiology* 19: 233-256, 1932.
15. Halkin, H., Ueber den Einfluss der Becquerelstrahlen auf die Haut. *Arch. Dermat. u. Syph.* 65: 201-220, 1903.
16. Goldberg, S. V. Cited in *Das Radium in der Biologie und Medizin* by London, J. S., Leipzig, 1911, p. 56.
17. Bloom, W., and Bloom, M. A. Radiation Biology. Vol. I, Part II, p. 1119, McGraw-Hill Book Co., Inc., New York, 1954.
18. Warren, Shields. The histopathology of radiation lesions. *Physiol. Rev.* 24: 225-237, 1944.
19. Nödl, F. Über Gewebsveränderungen der menschlichen Haut nach Einwirkung von schnellen Elektronen. *Strahlentherapie* 92: 576, 1953.
20. Walbach, S. B. The pathologic histology of chronic x-ray dermatitis and early x-ray carcinoma. *J. of Med. Research* 16: 415, 1909.
21. Ellinger, F. The Biologic Fundamentals of Radiation Therapy. Elsevier Publishing Co., Inc., Chapt. XXII, New York, 1941.
22. Henshaw, P. S., Snider, R. S., and Riley, E. F. Aberrant tissue developments in rats exposed to beta rays. *Radiology* 52: 401-415, 1949.
23. Raper, J. R., and Barnes, K. K. Biological Effects of External Beta Radiation. Chapter 4, McGraw-Hill Book Co., Inc., First edition, New York, 1951.
24. Snider, R. S., and Raper, J. R. Biological Effects of External Beta Radiation. Chapter 9, McGraw-Hill Book Co., Inc. First edition, New York, 1951.
25. Lushbaugh, C. E., Spalding, J. F., and Hale, D. B. Report on sheep losses adjacent to the Nevada Proving Grounds. AEC Report Jan. 6, 1954.

26. Moritz, A. R., and Henriques, F. W. Effect of beta rays on the skin as a function of the energy, intensity, and duration of radiation. *J. Lab. Investigation* 1: 167, 1952.
27. Sulzberger, M. B., Baer, R. L., and Borota, A. Skin changes induced by low voltage roentgen radiation. AEC Report AECU-1616, n.d.
28. Dorn, H. F. Illness from cancer in the United States. Public Health Report, Reprint No. 2537, Govt. Printing Office, Jan. 1944.
29. Liebow, A. A., Warren, S., and De Coursey, E. Pathology of atomic bomb casualties. *Am. J. Path.* 25: 853, 1949.
30. Liebow, A. A. Effects produced on hair by atomic bombs. *Ann. New York Acad. Sc.* 53: 688, 1951.
31. Argyris, T. S. The relationship between the hair growth cycle and the response of mouse skin x-irradiation. *Am. J. of Anat.* 94: 439, 1954.
32. Ellinger, F. Effects of ionizing radiation on growth and replacement of hair. *Ann. New York Acad. Sc.* 53: 682, 1951.
33. Hance, R. T., and Murphy, J. B. Studies on x-ray effects. XV. The prevention of pigment formation in the hair follicles of colored mice with high voltage x-ray. *J. Exper. Med.* 44: 339, 1926.
34. Danneel, R., and Lubenow, E. Zur physiologie der Kälteschwarzung beim Russenkaninchen. II. Mitt., *Biol. Ztbl.* 56: 572, 1936.
35. Cameron, J. A. Hair color change in mice as indicators of the speed of x-ray effects. *Genetics* 23: 143, 1938.
36. Chase, H. B. Greying of hair. I. Effects produced by single doses of x-rays on mice. *J. Morphol.* 84: 57, 1949.
37. Palumbo, V. Ueber einige durch radioaktive Bestrahlungen hervorgerufene biologische Reaktionen. *Strahlentherapie* 56: 318, 1936.
38. Weiss, K. Zur Frage der Hyperpigmentation des Haares nach Temperäver Epilation. *Strahlentherapie* 69: 340, 1941.
39. Sutton, R. L., Jr. Transverse band pigmentation of fingernails after x-ray therapy. *J. A. M. A.* 150: 210, 1952.



Plate 5. Hyperpigmented raised plaques and bullae on dorsum of feet and toes at 28 days. One lesion on left foot shows deeper involvement. Feet were painful at this time. Case 67, age 14, F.



Plate 6. Lesions 10 days later. Bullae have broken, desquamation is essentially complete and lesions have healed. Feet no longer painful.

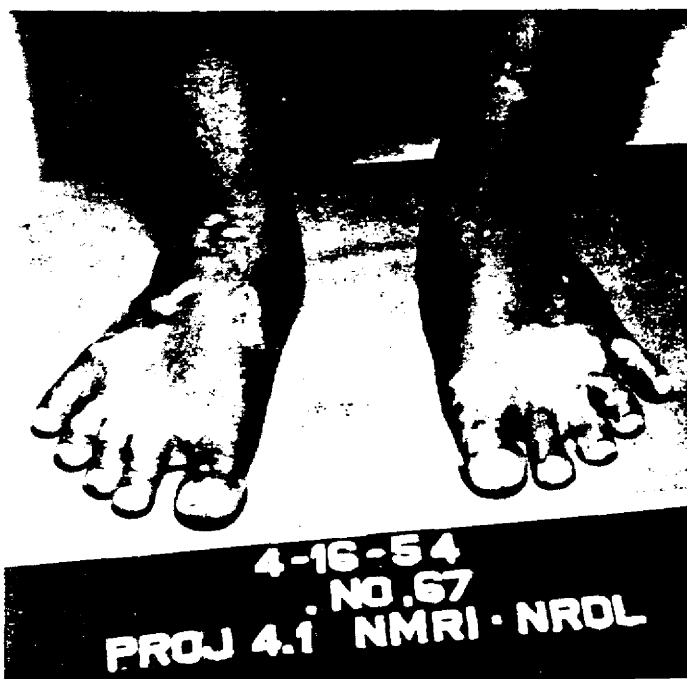


Plate 7. Lesions 6 days later than in Plate 6 showing repigmentation except for small scar on dorsum of left foot at site of deepest lesion.



Plate 8. Same case, 6 months later. Foot lesions have healed with repigmentation. Depigmented spots persist in small areas where deeper lesions were located.




Plate 1. Early hyperpigmented maculopapular neck lesions at 15 days. Case 39, age 15, F.



Plate 2. Neck lesions at 28 days. Wet desquamation. White color is calamine lotion. Case 78, age 37, F.

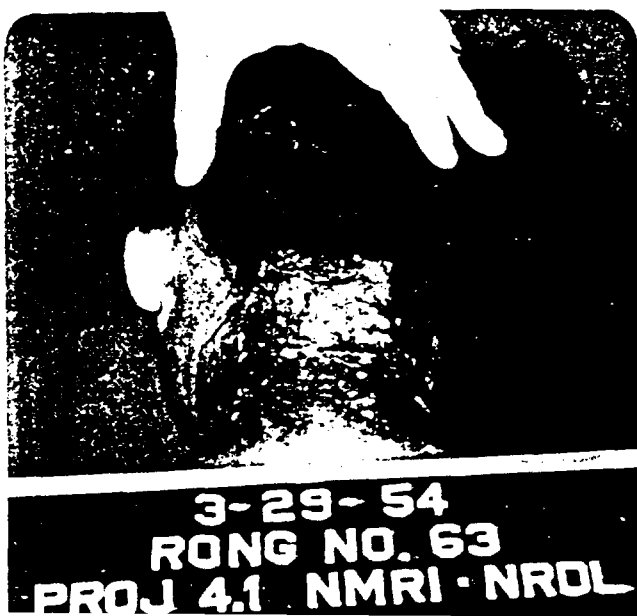

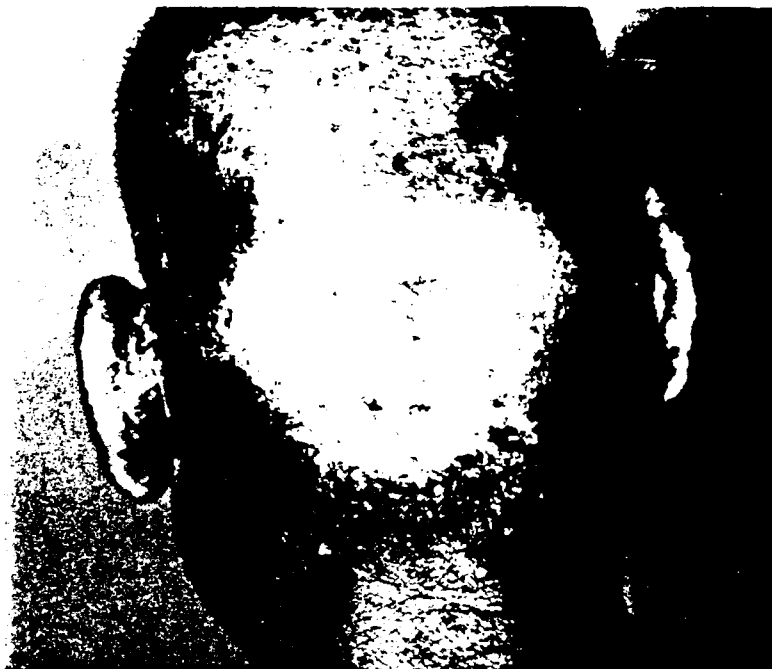


Plate 13. Desquamation of back of scalp at 28 days. Epilation occurred earlier in desquamated area. Note persistent ulceration of left ear. Case 79, age 41, M. Head has been shaved.



Plate 14. Eighteen days later. Scalp lesions have healed with repigmentation of skin. No hair growth evident in epilated areas. Ear ulceration persists with little improvement.




Plate 15. Same case showing complete regrowth of hair of normal color and texture at six months after exposure. Ear lesion has healed with considerable scarring. See Plate 16.



Plate 16. Ear lesion shown in Plate 15 magnified 20 times. Note atrophy and scaling of scar tissue. Telangiectatic vessels can be seen in the upper part of the picture.

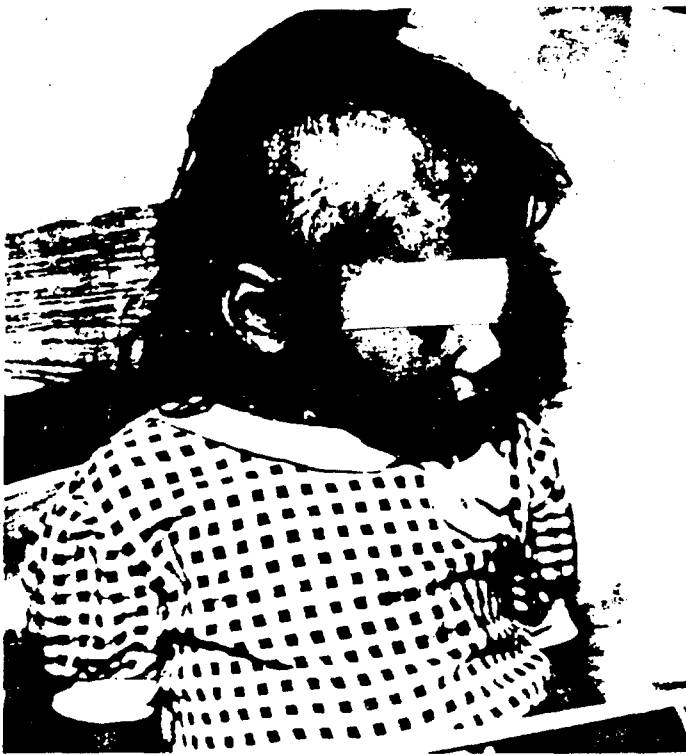

Plate 17. Epilation in 7 year old girl at 28 days. Case 72.



Plate 18. Same case as in Plate 17, six months after exposure showing complete regrowth of normal hair.

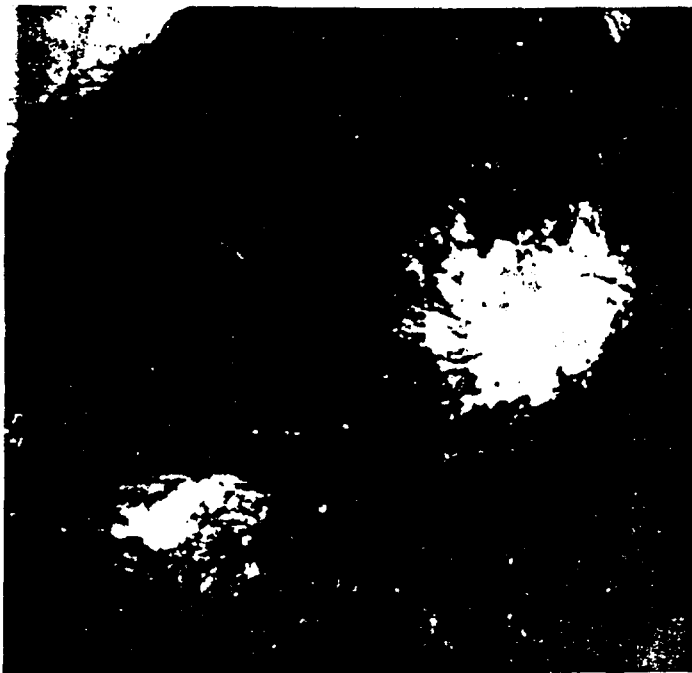

Plate 19. Spotty epilation with scalp lesions in 13 year old boy. Same case as Plates 9-12.

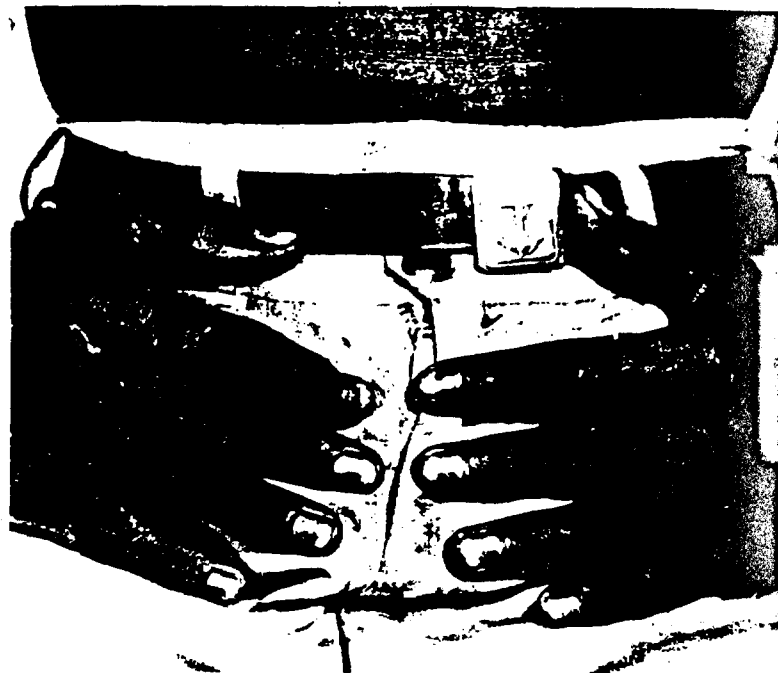


Plate 20. Pigmentation associated with finger nails. Has progressed to the end of the nailbed 6 months after exposure.





Plate 21.

(X100, H&E) *Epidermis*: Extensive transepidermal damage (with slightly less involved zones on either side). Loose lamination of stratum corneum, absence of stratum granulosum. Parakeratinization with exfoliation of pigment-containing cells. Disorganization of the malpighian layer. *Dermis*: Mild edema of pars papillaris with indistinct capillary loops. Perivascular cellular infiltrate (lymphocytes and mononuclear phagocytes), in superficial corium with telangiectasis. Case 26.

Plate 22.

(X100, H&E) *Epidermis*: Arcades of minimal damage occur in relation to excretory ducts of sweat glands. Stratum granulosum of good width and shows scant alteration. Underlying stratum malpighii shows decrease in pigment. In the deeper portion of the overlying, loosely laminated stratum corneum moderate amounts of pigment, however, are present. One narrow arcade of more severe transepidermal damage at the left of the photomicrograph shows alteration of the stratum granulosum with intercellular edema, pyknosis, swollen nuclei, and pigment scattered throughout. The latter is especially dense in the contiguous parakeratotic material. *Dermis*: A moderate cellular infiltrate, chiefly perivascular, is most pronounced in the superficial pars reticularis where there is a mild telangiectasis. Case 26.

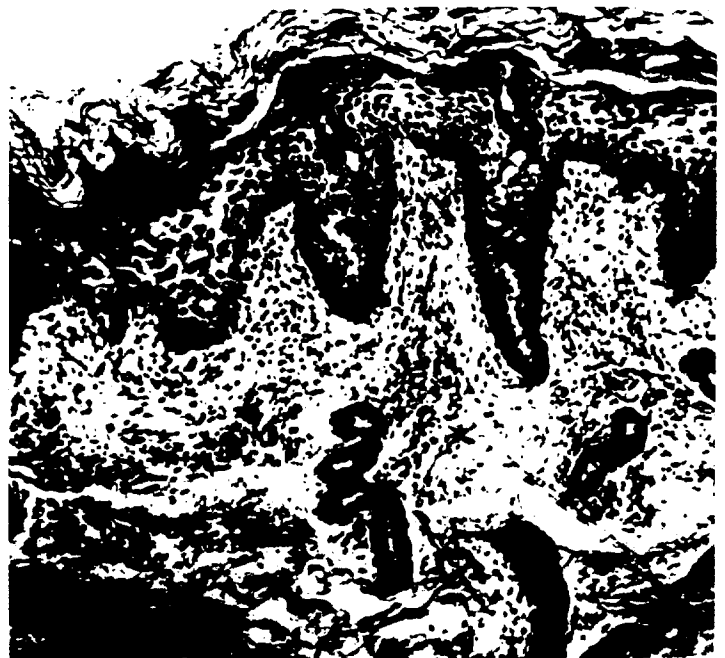




Plate 23.

(X400, H&E) Transepidermal damage with disorganization of the malpighian layer. Stratum granulosum absent. Malpighian and basal layer only two or three cells thick with exfoliation of pigment outward toward parakeratinized zone adjacent to stratum corneum. Some pigment laden chromatophores and histiocytes in pars papillaris of corium. Latter is edematous and infiltrated by moderate numbers of lymphocytes, and mononuclear phagocytes. Capillary loops indistinct. Case 26. 22 days post-exposure.

Plate 24.

(X100, H&E) Transepidermal damage with disorganization of the malpighian layer. Slight parakeratosis. Migration or exfoliation outward of pigment. Loose lamination of stratum corneum. Pigment laden chromatophores and histiocytes in superficial pars papillaris of corium. Marked cellular infiltration and edema of pars papillaris. Slight telangiectasis of superficial pars reticularis. Case 63.



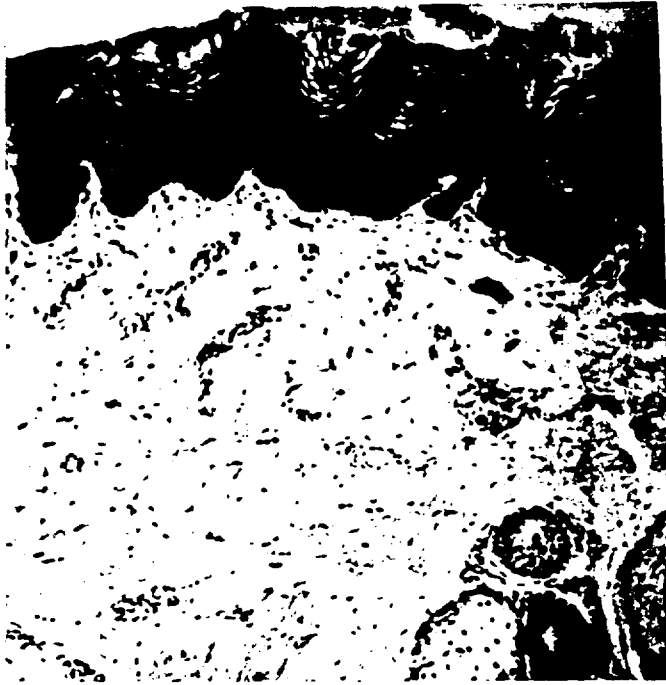

Plate 25. (53 days post-exposure). (X100, H&E) (Case # 75) Loose lamination of stratum corneum with outward papillary projections and resultant "rugose" appearance. Stratum granulosum of good width. Basal and malpighian layers distinct with pigment present. Slight edema of corium with mild telangiectasis and slight increase in perivascular lymphocytes and pericytes. Small somewhat atrophic hair follicle adjacent to sebaceous gland - in mid pars reticularis.



Plate 26. (53 days post-exposure). (X400, H&E) (Case #75) Same as 25. Occasional perinuclear cytoplasmic halos in mid stratum granulosum. Loosely laminated stratum corneum. (Pigment laden chromatophores in superficial corium along with occasional lymphocytes and mononuclear phagocytes.)



Plate 27. (46 days post-exposure). (X100, H&E) (Case #39) Narrow rugose epidermis with papillary extensions downward of stratum malpighii. Latter are heavily laden with melanotic pigment. Slight telangiectasis of pars papillaris and pars reticularis of dermis. Occasional pigment laden chromatophores in superficial dermis.



Plate 28. Shows lesions (third series of biopsies) at 6 months post-exposure. (X100, H&E) (Case #39) Note the marked diffuse atrophy of the stratum granulosum accompanied by narrow downward prolongations of the basal papillae. Moderate disturbance of keratinization and moderate telangiectasis are also seen.

Plate 29. Shows lesions (third series of biopsies) at 6 months post-exposure. (X100, H&E) (Case #24) Moderate focal atrophy of stratum corneum accompanied by paranuclear halos. Areas of depigmentation are prominent. In the dermis a moderate uniformly distributed telangiectasis is seen. There is also a perivascular distribution of cellular infiltrate.

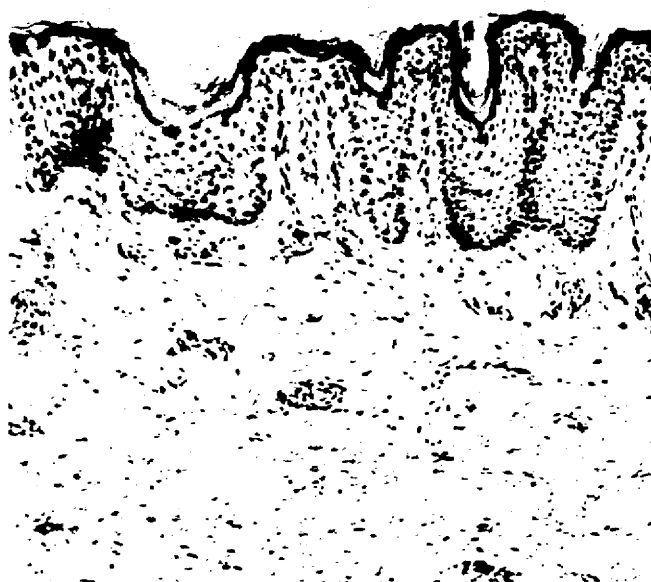



Plate 28. Shows lesions (third series of biopsies) at 6 months post-exposure. (X100, H&E) (Case #39) Note the marked diffuse atrophy of the stratum granulosum accompanied by narrow downward prolongations of the basal papillae. Moderate disturbance of keratinization and moderate telangiectasis are also seen.

Plate 29. Shows lesions (third series of biopsies) at 6 months post-exposure. (X100, H&E) (Case #24) Moderate focal atrophy of stratum corneum accompanied by paraneurhal halos. Areas of depigmentation are prominent. In the dermis a moderate uniformly distributed telangiectasis is seen. There is also a perivascular distribution of cellular infiltrate.

